

REVIEW

Pseudoxanthoma elasticum

S Laube, C Moss

Arch Dis Child 2005;90:754-756. doi: 10.1136/adc.2004.062075

Pseudoxanthoma elasticum (PXE) is a rare multisystem disorder characterised by progressive calcification and fragmentation of elastic fibres. Recent genetic advances have identified the underlying defect to the *ABCC6* gene on chromosome 16p13.1. Patients typically develop cutaneous, ocular, and cardiovascular manifestations but there is considerable phenotypic variability. The skin changes are usually apparent in adulthood, and rarely observed in childhood. Since the prognosis of PXE largely depends on the extent of extracutaneous organ involvement early recognition, intervention and lifestyle adjustments are important to reduce morbidity. First-degree family members should be carefully examined for any cutaneous or ophthalmologic features of PXE.

Pseudoxanthoma elasticum (PXE; synonym: Grönblad-Strandberg syndrome; OMIM #177850 and 264800) is a rare, inherited, multisystem disorder primarily affecting the skin, eyes, and cardiovascular system. It is characterised by progressive calcification and degeneration of elastic fibres. There is considerable spectrum of genetic mutations and wide inter- and intra-familial phenotypic variations. Mild forms of the disorder can easily be overlooked, and a negative family history does not exclude the diagnosis. It is important to recognise the disease early, in order to minimise the risk of systemic complications (box 1).

AETIOLOGY

The prevalence is estimated at 1 in 25 000–100 000 with an almost 2:1 female preponderance.¹ The genetic defect has been mapped to the *ABCC6* gene on chromosome 16p13.1.^{2,3} *ABCC6* encodes multidrug resistance associated protein 6 (MRP6), which belongs to the ABC (ATP binding cassette) transmembrane transporter family of proteins. Its exact biological function is not clear yet but it may play a role in cellular detoxification. Interestingly, MRP6 is highly expressed in the liver and kidneys but only low levels are found in tissues affected in PXE. It has therefore been suggested that PXE is primarily a metabolic disorder with secondary involvement of elastic fibres.⁴ Genetic studies have to date identified about 60 mutations, mainly missense and nonsense mutations, as well as large deletions (for details see OMIM website).²⁻⁴

The usual mode of inheritance is autosomal recessive, but some families with two generation involvement have been observed in keeping with a pseudodominant pattern.² Autosomal domi-

nant PXE has been reported in a few families with two-generation PXE but no molecular evidence has been shown so far.^{5,6} Considerable clinical intra- and inter-familial variability, in particular with regard to age of onset, complicate the assessment of inheritance patterns.

PATHOLOGY

The histology of PXE is characteristic. In skin lesions swollen, clumped, and fragmented elastic fibres and calcium deposits are found in the mid and deep reticular dermis. Similar changes occur in elastic fibres of the blood vessels, Bruch's membrane of the eye, endocardium, and other organs. Transepidermal elimination of altered calcified elastic fibres may occasionally be seen in PXE.

The use of elastic stains (for example, Verhoeff-van Gieson or Orcein) and stains for calcium deposits (for example, von Kossa) are recommended. Electron microscopy may be used to show the characteristic abnormalities. Initially the mineralisation of elastic fibre occurs in the core. As the disease progresses the outer rim becomes increasingly dense and eventually when maximum calcification is reached fragmentation occurs.⁷

Ultrastructurally, extracellular matrix components such as fibronectin, vitronectin, and proteoglycans associated with altered elastic fibres in PXE accumulate in lesional skin.⁸ It has been suggested that these matrix proteins which are not present in normal fibres have a high affinity to calcium ions or induce mineral precipitation. Raised levels of glycosaminoglycans have been found in affected skin and urine of some patients with PXE.⁹

CUTANEOUS MANIFESTATIONS

Most cases of PXE are diagnosed in the age group from 10 to 15 years but cutaneous lesions have been reported in infancy.^{7,10,11} Because of their subtle and asymptomatic nature there is an average diagnostic delay of nine years.⁷ Small, yellowish, flat papules develop typically on the neck, and may coalesce to form plaques giving the skin a "gooseflesh" or "plucked chicken" appearance (fig 1). The antecubital and popliteal fossae, axillae, inguinal, and periumbilical areas are often also involved. The lesions are asymptomatic but often of cosmetic concern. As the disease progresses the affected skin may become lax and wrinkled, hanging in folds. Generalised severe laxity of the skin is rare.¹²

Lesions on the mucous membranes, especially on the inner aspect of the lower lip are common. Occasionally calcium deposits may extrude from the skin in advanced disease, a condition described as "perforating PXE".^{11,13} Other unusual clinical presentations of PXE include numerous acneiform lesions, chronic granulomatous

See end of article for authors' affiliations

Correspondence to: Dr S Laube, University Hospital of North Staffordshire, Department of Dermatology, Hartshill Road, Stoke-on-Trent ST4 7PA, UK; slaube@doctors.org.uk

Accepted
3 November 2004

Box 1 Criteria for the diagnosis of PXE (adapted from Lebwohl *et al*¹⁴)

Major criteria

- Characteristic skin signs (yellow cobblestone lesions in flexural areas)
- Characteristic ophthalmologic features (angioid streaks, peau d'orange, maculopathy)
- Characteristic histological features of lesional skin (elastic tissue and calcium or von Kossa stains)

Minor criteria

- Characteristic histological features of non-lesional skin (elastic tissue and calcium or von Kossa stains)
- Family history of PXE in first-degree relatives

Category I patients fulfil all three major criteria and definitely have PXE. However, in children ocular changes are not required to establish the diagnosis as they often do not develop until early adulthood. Category II patients do not have typical skin lesions but have either angioid streaks with at least one minor criterion, or two minor criteria

nodules, and brown macules in a reticulate pattern.¹¹ Biopsy of scars and flexural skin may be helpful when PXE is suspected in the absence of characteristic skin lesions.¹⁴

OCULAR MANIFESTATIONS

The characteristic eye signs of PXE are angioid streaks, which are irregular, reddish-brown, or grey lines that radiate from the optic disc. Angioid streaks appear to be present in at least 85% of patients with PXE and the typical age of onset is between 15 and 25 years.^{7 13} They result from degeneration and calcification of the elastic fibres of the retina leading to breaks in the Bruch's membrane. Retinal haemorrhages, neovascularisation, and scarring may occur and can lead to loss of central vision. Some authors estimate the frequency of visual impairment as high as 50–70% of cases.^{7 15} Major vascular abnormalities at the optic disc such as arteriovenous anastomosis have been found in PXE patients with angioid streaks.¹⁶

Angioid streaks are not pathognomonic and have been described in a variety of other systemic disorders including Ehlers–Danlos syndrome, Paget's disease of the bone, Marfan's syndrome, sickle cell anaemia, thalassaemia, and lead poisoning.

The first ocular sign is often *peau d'orange* appearance (a yellowish mottled hyperpigmentation of the retina) which may precede angioid streaks by up to 10 years.⁷ Other less common findings include colloid bodies, macular degeneration, optic nerve head drusen (whitish-yellow irregularities of the optic disc), and "owls eyes" (paired hyperpigmented spots).^{17 18}

CARDIOVASCULAR MANIFESTATIONS

Degeneration of the elastic laminae of medium sized arteries and calcium deposition are the cause of vascular manifestations of PXE.

Clinically, intermittent claudication is often the first sign of accelerated atherosclerosis and the most common cardiovascular symptom, occurring in 30% of patients. Coronary artery disease and renovascular hypertension may occur at a much younger age in PXE patients and can result in angina pectoris, myocardial infarction, congestive cardiac failure, renal failure, or stroke. Although cardiovascular disease rarely presents before the third or fourth decade it has been reported in children as young as 9 years of age.^{7 18 19}

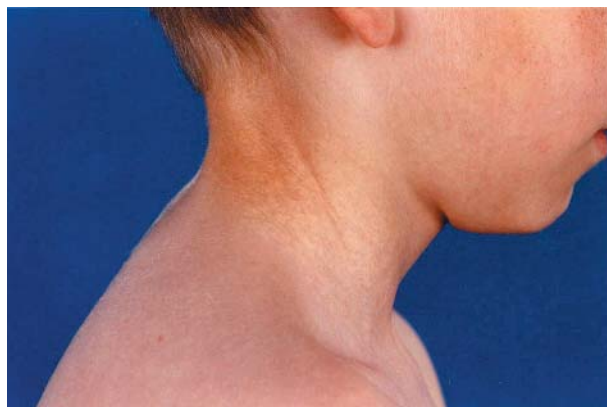


Figure 1 Characteristic yellow papules on the neck. Parental consent was obtained for publication of this figure.

Echocardiography may show marked calcification of the atrial and ventricular endocardium, valves, and calcified thrombi, which can result in mitral valve prolapse, mitral valve stenosis, or restrictive cardiomyopathy.²⁰ On renal ultrasonography a characteristic hyperechogenicity with dotted pattern has been reported in patients with PXE, possibly reflecting the calcified elastic layers of the arteries.²¹ Similar sonographic findings were seen in spleen and pancreas.

About 10% of PXE patients experience bleeding complications, especially gastrointestinal haemorrhage, due to fragility of calcified submucosal vessels. Bleeding may occur without warning and has been described in children and teenagers.^{18 22} Bleeding may also affect other organs such as the cerebrovascular system, uterus, urinary tract, or joints.^{10 22}

PXE-LIKE CONDITIONS

A PXE-like syndrome with cutaneous, ocular, and vascular manifestations has been described in patients with thalassaemia and sickle cell disease.²³ It is an acquired condition and age dependent with generally late onset.

Localised acquired PXE is a disorder occurring predominantly in black women with recurring abdominal distension, for example pregnancies or ascites.²⁴ Typical skin lesions develop predominantly in the periumbilical area but without systemic features and negative family history.

Papillary dermal elastolysis is an acquired cutaneous disorder, which mainly affects women aged 60–80 years.²⁵ It is characterised by white-yellow papules resembling PXE; histologically there is loss of elastin in the papillary dermis. In contrast, actinic elastosis shows thickening, yellow discoloration, and marked wrinkling of sun exposed skin areas. Histologically there is an increase in dermal elastosis.

PXE-like skin lesions have also been observed in long-standing end-stage renal disease, L-tryptophan induced eosinophilia myalgia syndrome, and amyloid elastosis as well as with D-penicillamine, cutaneous exposure to calcium salts, and salpeter.^{13 17 24}

MANAGEMENT AND PROPHYLAXIS

Patients with PXE typically have a normal life span but morbidity and mortality depend on the extent of systemic involvement. Many of the pathological changes are irreversible. However, prophylactic measures and lifestyle adjustments can be used to minimise the risk of complications (box 2). Early diagnosis of PXE is therefore paramount.

If the appearance of skin lesions becomes a cosmetic problem plastic surgery has been used successfully.²⁶ However, wound healing appears to be slower than usual

Box 2 Suggested management of patients with PXE

Eye examination

- 6–12 monthly check by ophthalmologist
- Regular use of Amsler grid by patients to monitor central vision (chart consisting of evenly spaced horizontal and vertical lines with a small dot in the centre of the grid)

Cardiology assessment

- Yearly check of blood pressure, peripheral pulses, and for heart murmurs
- If abnormal findings, refer to cardiologist for further investigations, e.g. echocardiogram

Laboratory tests

- In children low threshold/in adults 6–12 monthly
- Blood count, ferritin, serum lipids, urinalysis

Medicaments

- Avoidance of non-steroidal anti-inflammatory analgesics and warfarin
- Selective use of aspirin for prevention of thromboembolic events in high risk patients
- Avoidance of oestrogens, e.g. oral contraceptive pill, HRT

Diet

- Avoid high cholesterol
- Moderate calcium intake

Lifestyle

- Regular exercise but avoid contact sports and straining
- Weight control
- Avoidance of smoking

Genetic counselling

and in some patients extrusion of calcium through the healing scars occurred postoperatively.

Patients with PXE should receive an ophthalmology and cardiology assessment on a regular basis. Laser photocoagulation can prevent retinal haemorrhage but recurrence is relatively common.¹³ Other risk factors for cardiovascular disease, such as raised serum lipids and hypertension, should be treated. Regular exercise is important but contact sports with the possibility of head trauma—that is, boxing, wrestling, football, and heavy straining such as weight lifting, should be avoided. In both children and adults there should be a low threshold for using laboratory tests to exclude gastrointestinal bleeding. To reduce the risk of bleeding, platelet inhibitors such as aspirin and non-steroidal anti-inflammatory drugs as well as warfarin should generally be avoided. However, low dose aspirin may occasionally be required in the prevention of myocardial and cerebrovascular infarction.¹³

Serum calcium and phosphate levels are usually normal. Excessive dietary intake of calcium should be avoided in childhood and adolescence because a correlation of severity of PXE with high calcium intake has been suggested.²⁷

Most women with PXE have a normal pregnancy but may rarely experience gastric or uterine bleeding and are more likely to develop perineal tears and abdominal striae.

Because of marked phenotypic variability, counselling requires careful screening of first-degree relatives.¹⁰ A skin biopsy of suspicious lesions, flexural skin, or scar tissue may

be necessary.¹⁴ Fundoscopy is recommended as eye changes may precede cutaneous signs. Patients and their families should also receive genetic counselling. All the current evidence suggests that the inheritance pattern in PXE is usually autosomal recessive. Recurrence risks in sporadic cases are therefore generally low. Molecular genetic testing is available only on a research basis.

Authors' affiliations

S Laube, C Moss, Department of Dermatology, Birmingham Children's Hospital, Steelhouse Lane, Birmingham B4 6NH, UK

Competing interests: none

Consent was obtained for publication of figure 1

REFERENCES

- 1 Bercovitch L, Terry P. Pseudoxanthoma elasticum 2004. *J Am Acad Dermatol* 2004;**51**:S13–14.
- 2 Ringpfeil F, Lebowitz MG, Christiano AM, et al. Pseudoxanthoma elasticum: mutations in the gene encoding a transmembrane ATP-binding cassette (ABC) transporter. *Proc Natl Acad Sci U S A* 2000;**97**:6001–6.
- 3 Bergen AA, Plomp AS, Schuurman EJ, et al. Mutations in *ABCC6* cause pseudoxanthoma elasticum. *Nat Genet* 2000;**25**:228–31.
- 4 Ringpfeil F, Pulkkinen L, Uitto J. Molecular genetics of pseudoxanthoma elasticum. *Exp Dermatol* 2001;**10**:221–8.
- 5 Plomp AS, Hu X, de Jong PT, Bergen AA. Does autosomal dominant pseudoxanthoma elasticum exist? *Am J Med Genet* 2004;**126A**:403–12.
- 6 Chassaing N, Martin L, Mazereeuw J, et al. Novel *ABCC6* mutations in pseudoxanthoma elasticum. *J Invest Dermatol* 2004;**122**:608–13.
- 7 Hacker SM, Ramos-Caro FA, Beers BB, et al. Juvenile pseudoxanthoma elasticum: recognition and management. *Pediatr Dermatol* 1993;**10**:19–25.
- 8 Contri MB, Boraldi F, Taparelli F, et al. Matrix proteins with high affinity for calcium ions are associated with mineralization within elastic fibers of pseudoxanthoma elasticum dermis. *Am J Pathol* 1996;**148**:596–77.
- 9 Rodriguez-Cuatero A, Garcia-Vera E. Pseudoxanthoma elasticum: a study of urinary glycosaminoglycan levels in two cases. *Br J Dermatol* 1997;**137**:473–4.
- 10 Sherer DW, Bercovitch L, Lebowitz M. Pseudoxanthoma elasticum: significance of limited phenotypic expression in parents of affected offspring. *J Am Acad Dermatol* 2001;**44**:534–7.
- 11 Li T-H, Tseng C-R, Hsiao G-H, et al. An unusual cutaneous manifestation of pseudoxanthoma elasticum mimicking reticulate pigmentary disorders. *Br J Dermatol* 1996;**134**:1157–9.
- 12 Uenishi T, Uchiyama M, Sugiura H, et al. Pseudoxanthoma elasticum with generalized cutaneous laxity. *Arch Dermatol* 1997;**133**:664–6.
- 13 Uitto J, Ringpfeil F, Pulkkinen L. Pseudoxanthoma elasticum. In: Bologna JL, Jorizzo JL, Rapini RP, eds. *Dermatology*. London: Mosby, 2003:1524–6.
- 14 Lebowitz M, Phelps RG, Yannuzzi L, et al. Diagnosis of pseudoxanthoma elasticum by scar biopsy in patients without characteristic skin lesions. *N Engl J Med* 1987;**317**:347–50.
- 15 Struk B, Neldner KH, Rao VS, et al. Mapping of both autosomal recessive and dominant variants of pseudoxanthoma elasticum to chromosome 16p13.1. *Hum Mol Genet* 1997;**6**:1823–8.
- 16 Secrétan M, Zografos L, Guggisberg D, et al. Choriorretinal vascular abnormalities associated with angioid streaks and pseudoxanthoma elasticum. *Arch Ophthalmol* 1998;**116**:1333–6.
- 17 Lebowitz M, Neldner K, Pope FM, et al. Classification of pseudoxanthoma elasticum: report of a consensus conference. *J Am Acad Dermatol* 1994;**30**:103–7.
- 18 Schachner L, Young D. Pseudoxanthoma elasticum with severe cardiovascular disease in a child. *Am J Dis Child* 1974;**127**:571–5.
- 19 Nishida H, Endo M, Koyanagi H, et al. Coronary artery bypass in a 15-year-old girl with pseudoxanthoma elasticum. *Ann Thorac Surg* 1990;**49**:483–5.
- 20 Rosenzweig BP, Guarneri E, Kronzon I. Echocardiographic manifestations in a patient with pseudoxanthoma elasticum. *Ann Intern Med* 1993;**119**:487–91.
- 21 Suarez MJ, Garcia JB, Orense M, et al. Sonographic aspects of pseudoxanthoma elasticum. *Pediatr Radiol* 1991;**21**:538–9.
- 22 Heaton JP, Wilson JW. Pseudoxanthoma elasticum and its urological implications. *J Urol* 1986;**135**:776–7.
- 23 Aessopos A, Farmakis D, Loukopoulou D. Elastic tissue abnormalities resembling pseudoxanthoma elasticum in β thalassemia and the sickling syndromes. *Blood* 2002;**99**:30–5.
- 24 Neldner KH, Martinez-Hernandez A. Localized acquired cutaneous pseudoxanthoma elasticum. *J Am Acad Dermatol* 1979;**1**:523–30.
- 25 Ohnishi Y, Tajima S, Ishibashi A, et al. Pseudoxanthoma elasticum-like papillary dermal elastolysis: report of four Japanese cases and an immunohistochemical study of elastin and fibrillin-1. *Br J Dermatol* 1998;**139**:141–4.
- 26 Viljoen DL, Bloch C, Beighton P. Plastic surgery in pseudoxanthoma elasticum: experience in nine patients. *Plast Reconstr Surg* 1990;**85**:233–8.
- 27 Hamamoto Y, Nagai K, Yasui H, et al. Hyperreactivity of pseudoxanthoma elasticum-affected dermis to vitamin D3. *J Am Acad Dermatol* 2000;**42**:685–7.