

## SHORT REPORT

## Negative results of antiendomysial antibodies: long term follow up

J Kwiecien, K Karczewska, M Lukasik, J Kasner, A Dyduch, A Zabka, J Sulej, S Ronczkowski

*Arch Dis Child* 2005;90:41–42. doi: 10.1136/adc.2003.048231

Fifteen patients with intestinal villous atrophy, but simultaneously negative results of antiendomysial antibodies (EMA) were studied. Two patients were finally diagnosed as having coeliac disease. The predictive value of negative results of EMA assessment in children suspected of coeliac disease is high, approaching 86.7%.

Coeliac disease (CD) is a lifelong disorder characterised by small bowel mucosal damage caused by a permanent hypersensitivity to dietary gluten in genetically susceptible individuals.<sup>1</sup> According to ESPGHAN (European Society for Paediatric Gastroenterology, Hepatology and Nutrition) criteria, the diagnosis of CD requires demonstration of typical histological findings on small bowel biopsy and positive serological tests specific to CD. Among the serological tests, serum antiendomysial antibodies (EMA) have been regarded as being most specific and sensitive for CD.<sup>2</sup> Unfortunately there are some patients who are EMA negative in spite of biopsy proven CD. There has been no long term observation of patients with villous atrophy, who are EMA negative. We therefore undertook a retrospective analysis to determine the final diagnosis in children with intestinal villous atrophy, but who are negative for EMA.

## METHODS

We analysed data from patients suspected of CD and who had been observed for at least three years. During the period 1985–2000 we performed EMA tests in over 1300 children suspected of having CD. Among them we found 34 patients having subtotal or total intestinal villous atrophy at the time of first intestinal biopsy, with simultaneously negative results of EMA testing.

All EMA tests were performed in the same laboratory, by the same person. The presence of EMA antibodies was detected using the methodology described by Chorzeliski and colleagues.<sup>3</sup> Sera were tested by indirect immunofluorescence for IgA-EMA on 4 µm sections of fresh frozen monkey oesophagus with an antihuman IgA conjugate.

Intestinal biopsy was performed using the Crosby suction capsule. Biopsy samples were obtained at the level of the ligament of Treitz. The sections were stained using the routine haematoxylin-eosin method and assessed by the same pathologist, who was unaware of the clinical and serological findings of the subject. Villous atrophy was diagnosed when the biopsy result corresponded to type 3 (destructive lesion) in the classification of Marsh.

## RESULTS

A total of 15 children (12 girls and 3 boys) out of 34, have reached the end of the long term follow up with three biopsies according to the Interlaken criteria (fig 1). The mean age of these 15 children at the time of the first intestinal

biopsy was 30.47 months (SD 38.35, range 8–143). One child (6.7%) had IgA deficiency, but the assessment of IgG-EMA antibodies also yielded negative results. Mean time of observation was 66.80 months (SD 24.64, range 36–121). In 13 patients (86.7%), CD was eventually excluded. Two patients (13.3%) were finally diagnosed as having permanent gluten intolerance.

Patient no. 1 (female, AK) was 13 months old at the time of the first biopsy (described as subtotal villous atrophy). A second intestinal biopsy, performed after three years of gluten free diet, revealed normal intestinal mucosa, but after 12 months of gluten challenge, mucosal relapse with clinical symptoms of malabsorption syndrome and positive IgA-EMA (1/20) was observed. Therefore, CD was finally diagnosed at the age of 5 years and 9 months.

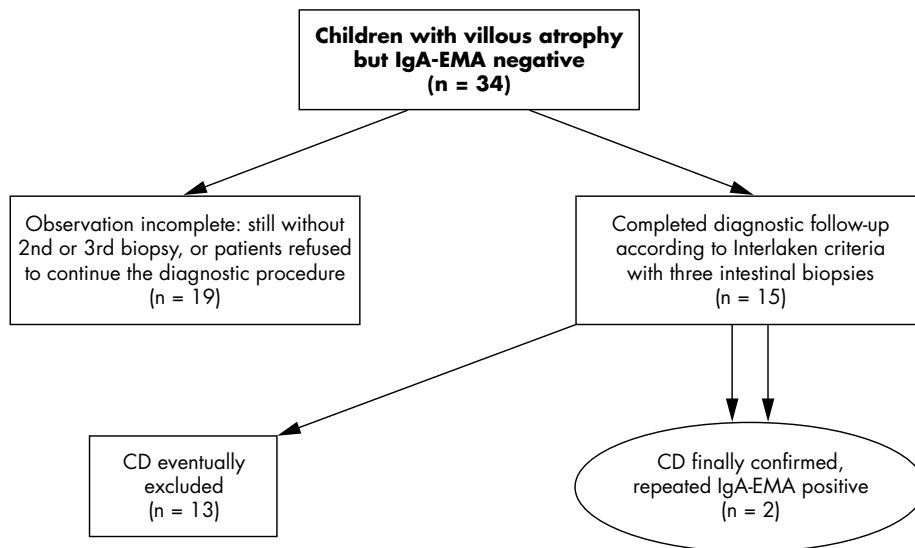
Patient no. 2 (female, MK) was 11 months old at the time of the first intestinal biopsy (described as total villous atrophy). After 2.5 years of gluten free diet, her parents refused the second biopsy and introduced a gluten containing diet by themselves. After two years of free diet, subtotal villous atrophy was again discovered, but EMA was still negative. A gluten free diet was accepted again for two years. Its consequence was normalisation of the intestinal mucosa. The girl was then again rechallenged with gluten. Surprisingly, three years later (that is, over nine years after the first intestinal biopsy), there was immunological relapse (IgA-EMA titre 1/160). Intestinal biopsy revealed subtotal villous atrophy and CD was diagnosed. The girl was then 10 years and 3 months old.

## DISCUSSION

Looking for studies similar to our work, we have found only two reports dedicated to this problem. The first described three children, and clinical observation lasted scarcely two years.<sup>4</sup> In this paper, Gandolfi *et al* found that two children were clinically well after discontinuing the gluten free diet. The third child was strongly suspected of having CD. Unfortunately, the child had life-threatening septicaemia and died despite intensive care. Picarelli *et al* selected 18 IgA-EMA negative children with clinical suspicion of CD and total or subtotal intestinal mucosa atrophy.<sup>5</sup> Unfortunately, observation of these patients ended after 8–10 months of gluten-free diet without further gluten challenge.

The typical picture of intestinal villous atrophy is regarded as highly specific for CD. Nevertheless there are some pitfalls in diagnosing CD in children. Infections such as severe rotavirus enteritis, giardiasis, or tropical sprue can cause villous flattening which could be indistinguishable from that of CD. Furthermore, some cases of cows' milk protein or soy protein intolerance are associated with lesions similar to those of CD.<sup>1,2</sup> Moreover, assessment of EMA antibodies

**Abbreviations:** CD, coeliac disease; ESPGHAN, European Society for Paediatric Gastroenterology, Hepatology and Nutrition; EMA, antiendomysial antibodies



**Figure 1** The final outcome of children with intestinal villous atrophy and negative EMA testing at the time of first biopsy.

requires immunofluorescence technique, which is dependent on subjective interpretation and could lead to interobserver variation. It is also known that children younger than 2 years do not develop a full immune response, and up to 20% may have false negative results of EMA.<sup>6</sup> This happened in our study. Both false negative results were found in patients aged under 2 years.

### Conclusions

In most patients with intestinal villous atrophy and negative results of antiendomysial antibodies, coeliac disease may be finally excluded. However, one should be aware that in a proportion of patients, mucosal and serological relapse develops only after many years of gluten challenge.

### Authors' affiliations

**J Kwiecien, K Karczewska, J Kasner, A Zabka**, Department of Paediatric Gastroenterology, Allergology and Developmental Disorders, Medical University of Silesia, Zabrze, Poland

**M Lukasik, S Ronczkowski**, Paediatric Day-Care Center, Medical University of Silesia, Zabrze, Poland

**A Dyduch**, Department of Paediatric Nephrology, Endocrinology and Metabolic Disorders. Medical University of Silesia, Zabrze, Poland

**J Sulej**, Department of Dermatology, Warsaw Medical University, Warszawa, Poland

Correspondence to: Dr J Kwiecien, Department of Paediatric Gastroenterology, Allergology and Developmental Disorders, Medical University of Silesia, ul. 3-go Maja 13/15, 41-800 Zabrze, Poland; jkgastro@mp.pl

Accepted 26 April 2004

### REFERENCES

- 1 Mäki M, Collin P. Coeliac disease. *Lancet* 1997;**349**:1755-9.
- 2 Walker-Smith JA, Guandalini S, Schmitz J, et al. Report of Working Group of European Society for Pediatric Gastroenterology and Nutrition: revised criteria for diagnosis of coeliac disease. *Arch Dis Child* 1990;**65**:909-11.
- 3 Chorzeński TP, Beutner EH, Sulej J, et al. IgA anti-endomysium antibody. A new immunological marker of dermatitis herpetiformis and coeliac disease. *Br J Dermatol* 1984;**111**:395-402.
- 4 Gandolfi L, Catassi C, Garcia S, et al. Antiendomysial antibody test reliability in children with frequent diarrhoea and malnutrition: is it coeliac disease? *J Pediatr Gastroenterol Nutr* 2001;**33**:483-7.
- 5 Picarelli A, Sabbatella L, DiTola M, et al. Coeliac disease diagnosis in misdiagnosed children. *Pediatr Res* 2000;**48**:590-2.
- 6 Burgin-Wolff A, Gaze H, Hadziselimovic F, et al. Anti-gliadin and anti-endomysium antibody determination for coeliac disease. *Arch Dis Child* 1991;**66**:941-7.