

CASE REPORT

Pantoea agglomerans as a cause of septic arthritis after palm tree thorn injury; case report and literature review

A Kratz, D Greenberg, Y Barki, E Cohen, M Lifshitz

Arch Dis Child 2003;88:542–544

We report the case of a 14 year old healthy boy, who was admitted six weeks after being injured by a palm tree thorn, with limping caused by pain and swelling in his right knee. An ultrasound examination revealed a foreign body in the posterior lateral aspect of the right knee. *Pantoea agglomerans* was identified in the synovial fluid. The patient underwent two arthrotomies and was treated with amoxicillin-clavulanate intravenously for three weeks. The postoperative course was uneventful, and joint function returned to normal.

A review of the literature between 1953 and 2002 revealed that bacterial growth after plant thorn injuries is reported infrequently. Yet when reported, *Pantoea agglomerans* is the most common organism found. Therefore, it must be considered and suspected in "aseptic" cases of arthritis, when there is a history of a plant thorn injury. We also emphasise the efficacy of ultrasound examination in these cases to identify the presence and location of a plant thorn.

A 14 year old healthy boy was admitted to the hospital with pain and swelling in his right knee. He reported that six weeks prior to admission he had tripped over a palm tree branch and a thorn had penetrated his right knee. At that time, mild swelling and pain had been observed in the area of his right knee, and he had been treated with oral amoxicillin-clavulanate (2 g/day) for 10 days. The swelling and pain resolved. Two days prior to admission, notable swelling and pain in his right knee was observed.

Physical examination on admission showed an afebrile patient in good condition. His right knee was warm, swollen, and tender. Considerable limitation of active and passive range of motion was noted. Blood leucocyte count was 8.15×10^6 cells/l with 74% neutrophils. Erythrocyte sedimentation rate was 115 mm/h. Radiographs of the knee showed only soft tissue swelling, and no foreign body was detected. An arthrocentesis yielded 80 ml of purulent fluid. Direct microscopic examination of the fluid revealed many leucocytes, but no bacteria. Laboratory examination of the joint fluid showed 92.8×10^6 leucocytes/l with 86% neutrophils. A radioisotope scan with technetium was performed, showing an increased uptake in soft tissue and in the articular space.

The case was diagnosed as septic arthritis, and empiric treatment with cloxacillin (2 g four times daily) intravenously was started. Growth of a Gram negative bacillus from the joint fluid was detected in the BACTEC Peds Plus F broth (Becton Dickinson, Meylan, France). The final identification of the bacteria by the Vitec system (bioMerieux, Hazelwood, MO) was *Pantoea agglomerans*. Based on the strain susceptibility, treatment was replaced by intravenous amoxicillin-clavulanate (3 g/day). Ultrasound examination of the knee showed fluid accumulated in the suprapatellar bursa, and a foreign body, approximately 8 mm long, in the posterior lateral aspect of the knee (fig 1).

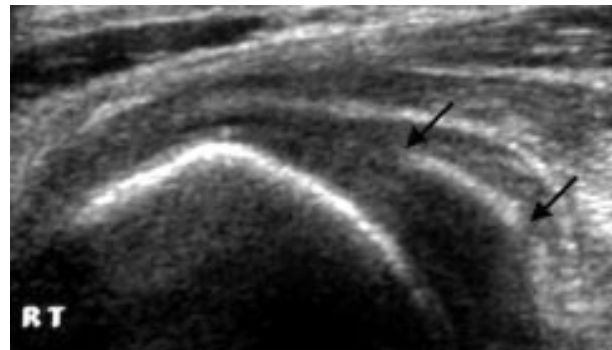


Figure 1 A foreign body with approximate length of 8 mm (the date palm thorn) is seen in the posterior lateral aspect of the knee (between the black arrows).

The patient underwent an arthrotomy with joint irrigation, but no foreign body was found. Intravenous antibiotic therapy was continued; the patient remained afebrile, and the swelling decreased, but there was still a limited range of movement and no further clinical improvement. The erythrocyte sedimentation rate was still raised (100 mm/h). A second ultrasound examination showed fragments of the foreign body lateral to the former location. The patient underwent a second arthrotomy. A small pouch, containing pus and surrounded by tiny fragments of thorn, was found and removed. Postoperative ultrasound examination revealed no trace of foreign body remnants. The patient remained hospitalised for one further week. The postoperative course, including a four week follow up examination, was uneventful, and joint functioning returned to normal.

DISCUSSION

Arthritis caused by plant thorn penetration is a well known medical condition, especially among children.^{1–9} It has been described following injuries from thorns of several kinds of plants, including palm, yucca, hawthorn, bougainvillea, sentry plant, blackthorn, cactus, and rose thorn.^{1–9}

The thorn of the date palm (*Phoenix dactylifera*; fig 2) is particularly dangerous as the tip (distal 0.5–1.5 cm; fig 3) dries out much faster than the remaining parts of the thorn, and therefore is prone to break off within the joint, disintegrating into very small particles.

Historically, failure to discover an organism in the joint fluid after a plant thorn injury led to the hypothesis, first published in 1953,² that the arthritis or synovitis after these injuries was the result of an allergic reaction, mostly caused by plant toxins, and hence was aseptic. A review of numerous reports of plant thorn arthritis and synovitis published between 1953 and 2002 revealed that reports of organisms found in cultures of joint fluid were very rare^{1–9} but when reported, *Pantoea agglomerans* was the most common organism (5 of 11 cases; table 1).

Table 1 Summary of all cases with positive cultures

Author	No. of cases reported	No. of positive cultures	Organism identification
Flatauer and Khan ⁵	1	1	<i>Pantoea agglomerans</i>
Stromqvist <i>et al</i> ⁶	1	1	<i>Pantoea agglomerans</i>
Olenginski <i>et al</i> ⁷	7	1	<i>Pantoea agglomerans</i>
De Champs <i>et al</i> ⁸	2	2	<i>Pantoea agglomerans</i>
Cahill and King ¹	10	2	a. <i>Staphylococcus aureus</i> b. Unspecified <i>Enterobacter</i>
Sugerman <i>et al</i> ⁴	5	3	a. <i>Staphylococcus albus</i> b. Gram negative rods
Freiberg <i>et al</i> ⁹	1	1	c. <i>Streptococcus α haemolytic</i> <i>Nocardia asteroides</i>



Figure 2 The date palm (*Phoenix dactylifera*).




Figure 3 The thorn tip of the date palm (0.5–1.5 cm) (black arrows).

Pantoea agglomerans (formerly named *Enterobacter agglomerans*, and earlier referred to as *Erwinia herbicola*) is a member of the *Enterobacteriaceae*. This Gram negative bacterium can be found in human and animal faeces and in plants. The earliest reports of human infections caused by this organism were published in the early 1970s.^{10 11}

The first case of arthritis caused by *Pantoea agglomerans* was reported in 1978, after a wooden splinter had penetrated a patient's knee.⁵ A similar case of knee arthritis after a blackthorn injury was reported seven years later.⁶ In 1991, Olenginski *et al* reported a series of seven patients suffering from plant thorn synovitis, of which only one case showed a positive joint fluid culture for *Pantoea agglomerans*.⁷ De Champs *et al* reported two cases of septic monoarthritis caused by *Pantoea agglomerans*.⁸

In all cases described, as well as in our case, the foreign body was not detected by x ray examination. In our patient the existence and location of a foreign body was confirmed by ultrasound examination. Most authors note the delay in establishing a correct diagnosis (up to nine months),⁸ since

the inflammation often develops long after the thorn injury has occurred. On the basis of a review of the literature, the recommended method to achieve complete recovery is arthrotomy and removal of the thorn.^{1–8}

Pantoea agglomerans has an important role in the pathogenesis of plant thorn arthritis after a thorn injury. It seems that many cases of “aseptic” arthritis after a plant thorn injury are actually *Pantoea agglomerans* septic arthritis. Inappropriate growth media and inaccurate identification methods could be the reason for negative results in culture identification. Therefore, the use of methods capable of recognising *Pantoea agglomerans* is recommended when a history of any thorn injury exists. An ultrasound or magnetic resonance imaging examination should be used to identify and locate suspected foreign bodies.¹² Removal of the foreign bodies by arthrotomy, combined with antibiotic therapy, seems to be the most effective treatment to achieve complete recovery.

.....
Authors' affiliations

A Kratz, M Lifshitz, Pediatrics Department D, Soroka University Medical Center and Faculty of Health Sciences, Ben-Gurion University of the Negev, Beer-Sheba, Israel

D Greenberg, Pediatric Infectious Disease Unit, Soroka University Medical Center

Y Barki, Department of Radiology, the Ultrasound Unit, Soroka University Medical Center

E Cohen, Department of Orthopedic Surgery, Soroka University Medical Center

Correspondence to: Dr M Lifshitz, Pediatrics Department D, Soroka University Medical Center, PO Box 151, Beer-Sheba 84101, Israel; matyl@bgumail.bgu.ac.il

Accepted 12 November 2002

REFERENCES

- 1 Cahill N, King JD. Palm thorn synovitis. *J Pediatr Orthop* 1984;4:175–9.
- 2 Karshner AG, Hanafee W. Palm thorns as a cause of joint effusion in children. *Radiology* 1953;60:592–5.
- 3 Kelly JJ. Blackthorn inflammation. *J Bone Joint Surg* 1966;48-B:474–7.
- 4 Sugerman M, Stobie DG, Quismorio FP, et al. Plant thorn synovitis. *Arthritis Rheum* 1977;20:1125–8.
- 5 Flatauer FE, Khan MA. Septic arthritis caused by *Enterobacter agglomerans*. *Arch Intern Med* 1978;138:788.
- 6 Stromqvist B, Edlund E, Lidgren L. A case of blackthorn synovitis. *Acta Orthop Scand* 1985;56:342–3.
- 7 Olenginski TP, Bush DC, Harrington TM. Plant thorn synovitis: an uncommon cause of monoarthritis. *Semin Arthritis Rheum* 1991;21:40–6.
- 8 De Champs C, Le Seaux S, Dubost JJ, et al. Isolation of *Pantoea agglomerans* after plant thorn and wood sliver injuries. *J Clin Microbiol* 2000;38:460–1.
- 9 Freiberg AA, Herzenberg JE, Sangeorzan JA. Thorn synovitis of the knee joint with *Nocardia pyarthrosis*. *Clin Orthop* 1993;287:233–6.
- 10 Bottone E, Schniereson SS. An emerging human pathogen. *Am J Clin Pathol* 1972;57:400–5.
- 11 Schniereson SS, Bottone E. *Erwinia* infections in man. *CRC Crit Rev Clin Lab Sci* 1973;4:341–55.
- 12 Stevens KJ, Theologis T, McNally EG. Imaging of plant-thorn synovitis. *Skeletal Radiol* 2000;29:605–8.

POSTCARD FROM THE ROAD.....

The black hole in my CV

When I was in my late twenties I heard myself saying something along the lines of “We can travel around the world when we retire”. Fortunately, as a consequence of the number of daft things I say, I do make an effort to listen to quite a lot of what comes out of my mouth. This particular inanity seemed to me to be, by several orders of magnitude, more stupid than anything I’d said in a long while.

It was shortly before this that I’d got an SpR post, together with an NTN and, out of the blue, a letter telling me the date on which I’d hopefully get my CCST. At this point I’d, theoretically, fall off the conveyor belt into, again hopefully, a consultant job. In this cynical state of mind the consultant job would be another conveyor belt, this time into retirement. The retirement itself—some 30 years hence—would provide the next opportunity to see a bit of the world.

This state of mind seemed immature, and, over an excellent cup of coffee, Kellie, who later became my wife, and I discussed talking with our respective employers about taking six months of unpaid leave for a career break. Nervously approaching my boss I found once again that I was able to prove one of my favourite things about life and getting older, namely: most of the things that I think I know are in fact wrong. This is a continuing and exciting theme for my life, and one which makes medicine particularly interesting. It would, in fact, be quite alright for me to step outside my rotation for six months and retain my NTN. (I’m afraid that at the time of writing this loophole has been closed with the pressure on postgraduate deans to get SpRs through the programme.)

In the next year or two of preparation—these things take a great deal of time—I augmented my six months with a year of work in Brisbane—the filling, if you like, in a travel sandwich. The Brisbane year grew to two en route, which is why I find myself writing this in a café in Oaxaca, Mexico, nearly 2½ years after leaving the UK, and on a date which roughly equals my original projected CCST.

I have to ask the same questions of my time spent travelling as I have elsewhere of my time working overseas. Firstly, what are the negatives?

I’d characterise these, chiefly, as expense and CV. The expense part is easy to imagine; six months without pay, at the same time as spending on travel. I used to say that I could

think of no one lying on their death bed and saying, “I’m really pleased we had that new kitchen six months sooner”. I’m more inclined these days to upgrade that estimate to at least 18 months, and throw in a bathroom too. But you shouldn’t confuse recognising an economic fact with regret; I’m entirely happy with this and I consider that the number of things I’ll be able to remember on my death bed—and all the times between here and then—were in fact very reasonably priced.

The CV part of it is tricky. I know a lot of folk who took a year off before entering university, and this is rarely criticised. But taking six months in the middle of a career is seen very differently in some quarters. One senior colleague quietly confided to me a similar—but different—adventure in his early career which was sufficient to make an interviewer comment “You don’t have much staying power, do you?”. Similarly I was advised by one senior academic that for any “serious” career I’d do well to disguise what I’ve come to think of as the black hole in my CV. Interestingly most senior colleagues in paediatrics, however, have expressed delight, fascination, and not a little jealousy at my adventure.

The question remains, shall I attempt to disguise my CV black hole? This becomes a bit of a moot point, since this postcard—complete with title—would appear in my CV, and would therefore be a bit of a giveaway. In any case, I don’t intend to hide it—this postcard is almost a way of making sure that I retain the courage of my convictions.

So, why not hide it? I’d need to list some of the positives—and I’m not sure where to begin. I think I’m a better, more rounded person than that twenty-something spouting rubbish. I think that I know more—but see my caveat above about most of what I know being wrong. I’ve spent time as an adult, free from tiredness, work, anxiety, and hassle. To use some clichés: I’ve woken up and smelt the coffee, I’ve stopped and smelt the roses, and I’ve done all this with someone I love.

And now I’m going to have another cappuccino, and this, and the thousand other cappuccinos, sunsets, landscapes, temples, smiles, and sights and smells and experiences should be enough to last me until I retire ...

I D Wacogne

Ian Wacogne is a consultant in general paediatrics at Birmingham Children’s Hospital, UK; ian.wacogne@btinternet.com