

## CASE REPORT

# Successful treatment with interferon alfa in infiltrating angioliipoma: a case presenting with Kasabach-Merritt syndrome

C Akyüz, S Emir, M Büyükpamukçu, N Büyükpamukçu, M Çağlar, G Kale, Ü Çalışkan

*Arch Dis Child* 2003;88:67–68

We report a case of infiltrating angioliipoma who presented with a large mass on the shoulder and the signs of Kasabach-Merritt syndrome. She improved dramatically within one month and the mass completely disappeared after six months of interferon treatment.

Infiltrating angioliipoma is a rare benign tumour characterised by infiltration of skeletal muscle by adipose tissue combined with angiomatous elements.<sup>1,2</sup> Infiltrating angioliipomas are usually unresectable surgically. Curative surgery is very mutilating in most cases. There is no well known alternative treatment for such unresectable infiltrating angioliipomas.

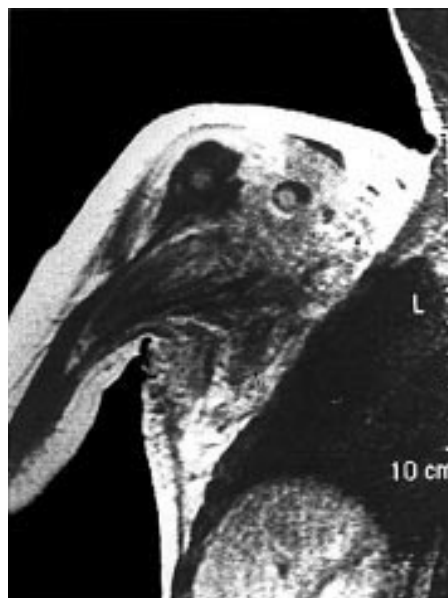
Interferons have been used therapeutically in a number of angiomatous diseases such as hemangiomas. A beneficial response to interferon therapy in life threatening hemangiomas has been reported.<sup>3–5</sup> We present a case of infiltrating angioliipoma who presented with thrombocytopenic purpura; interferon alfa was used to shrink the large mass on the shoulder.

### CASE REPORT

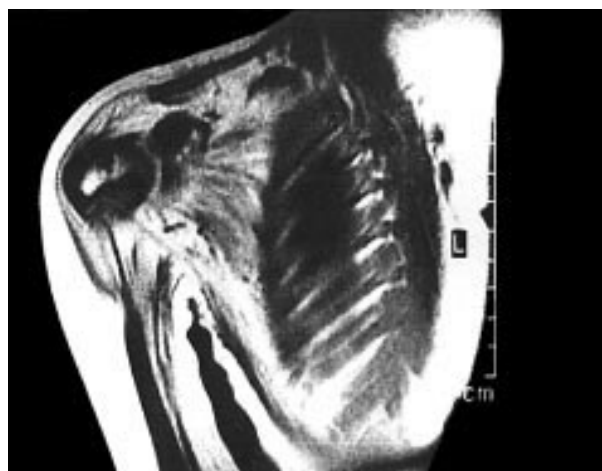
A 2 year old girl was admitted to Selçuk University Hospital with painful swelling on the right shoulder and several ecchymotic lesions on her body. On examination, there was a 4×5 cm soft tissue mass surrounding the right shoulder and axillar region. The mass was tender and caused significant limitation of arm movement. There were many various sized purpuric and ecchymotic lesions over the trunk and extremities.

Complete blood count revealed significant anaemia and thrombocytopenia (haemoglobin 77 g/l, white blood cells  $7.6 \times 10^9/l$ , platelets  $27 \times 10^9/l$ ). Blood smear findings were normal except for the absence of platelets. Bone marrow examination showed normocellular with an increase in megakaryocytes and erythroid hyperplasia. The coagulation profile revealed prolonged prothrombin and partial thromboplastin time, decreased fibrinogen, and increased fibrin degradation products. (prothrombin time 14.1 seconds; partial thromboplastin time 46.3 seconds; fibrinogen 2.7  $\mu\text{mol/l}$ ; fibrin degradation products >2000).

High dose methylprednisolone was initiated with the presumptive diagnosis of acute idiopathic thrombocytopenic purpura. The platelet count gradually increased after the first week of steroid therapy. The steroid dose was tapered and discontinued within two weeks. One month later she re-presented with complaints of a progressively enlarging mass on her shoulder and ecchymotic lesions on her body. Magnetic resonance imaging (MRI) showed an ill defined infiltrating solid mass with high signal intensity involving the anterior part of the right scapula, extending into the proximal metaphysis of the right humerus (fig 1). On pathological



**Figure 1** Initial MRI of right shoulder, showing infiltrating solid mass involving the anterior part of the right scapula.



**Figure 2** Post-treatment MRI of right shoulder, showing shrinkage of the mass.

examination of incisional biopsy, the mass was seen to be composed of mature adipose tissue, fibrous bands, skeletal muscle cells, and vascular tissue. She was referred to our hospital for further evaluation and treatment. Pathological findings led to a diagnosis of angioliipoma.

Since the mass was considered unresectable, high dose methylprednisolone was restarted to shrink the tumour. Although the size of the mass and thrombocytopenia improved dramatically within two months, all the symptoms reappeared when the steroid dose was reduced. Interferon alfa-2a (Roferon) 3 million units/m<sup>2</sup> three times a week was started. The platelet count increased gradually and the coagulation profile improved within one month. The mass reduced to 50% of its initial size within three months of treatment and completely disappeared after six months (fig 2). Interferon was discontinued in the ninth month of treatment. No recurrence was observed on follow up.

## DISCUSSION

Infiltrating angiolipoma is a very rare subgroup of angiolipomas that shows infiltration to the skeletal muscle and fibrocollagenous tissue. Gonzalez-Crussi *et al* first described six cases of unencapsulated lipomatous lesions containing blood vessels, skeletal tissue, and deep peripheral soft tissue, called "infiltrating angiolipoma".<sup>2</sup> It is usually non-encapsulated or partially capsulated, and much more deeply located than other non-infiltrating forms. In the series of Lin and Lin,<sup>1</sup> there were only two reported cases of infiltrating angiolipomas among 459 cases with various lipomatous tumours. The prognosis of infiltrating angiolipomas depends mainly on the site of the tumour. Since they usually infiltrate vital structures, complete resection of the mass is too mutilating in most cases.

It has been reported that some exceptional cases with angiolipoma could be misinterpreted as a hemangioma infiltrating the fat. The differential diagnosis of infiltrating angiolipoma should be made mainly with hemangiomas of the soft tissue. The former contains mature fatty tissue whereas there is no lipomatous component in the latter.

Some large, usually solitary, hemangiomas cause an entity known as Kasabach-Merritt syndrome. This is a coagulopathy characterised by a profound thrombocytopenia caused by platelet trapping within the lesion. It generally occurs early in the proliferating phase of a hemangioma and decreases when the hemangioma regresses.<sup>3</sup> Our case had the clinical and laboratory properties of Kasabach-Merritt syndrome such as thrombocytopenia, purpura, and ecchymoses. It is known that Kasabach-Merritt syndrome appears mostly in large hemangiomas. The most striking difference in this case is the occurrence of Kasabach-Merritt syndrome in a different pathological diagnosis such as infiltrating angiolipoma. Systemic corticosteroid therapy is the classical treatment for problematic hemangiomas with associated Kasabach-Merritt syndrome. However, the response rate has been variable and complications have been common. The use of interferon alfa as a valid alternative therapy has been suggested for hemangiomas that are unresponsive to corticosteroids. It has been reported that many infants with hemangiomas responded to interferon after failing steroid therapy.<sup>4,5</sup> Bielenberg *et al*

reported that there was evidence of high levels of positive angiogenic factors but absence of the endogenous inhibitor, interferon, in the proliferative tissue of hemangiomas.<sup>6</sup> The impact of interferons on several cellular and body functions, including cell proliferation, hormone stimulation, and tumour development has been reported in several studies. Childhood angiomatous tumours may respond to interferons. In the treatment of hemangioma, interferon exhibits its therapeutic effect by inhibiting angiogenesis and endothelial cell migration and proliferation.<sup>4,5</sup> It may also show beneficial effects in Kasabach-Merritt syndrome by decreasing platelet adherence and trapping by the endothelial cell surface. We used interferon in this case as the mass and its complications recurred after steroid tapering. Laboratory findings, including haemoglobin, platelet count, and coagulation profile resolved within one month. The volume of the mass also dramatically decreased to about 50% of the initial size within three months. To our knowledge, this is the first reported case of infiltrating angiolipoma presenting with Kasabach-Merritt syndrome in a child that responded to interferon therapy.

In conclusion, interferon may be considered in the treatment of various benign tumours containing vascular elements such as angiolipomas.

## Authors' affiliations

**C Akyüz, S Emir, M Büyükpamukçu**, Department of Pediatric Oncology, Hacettepe University Faculty of Medicine, 06100 Ankara, Turkey

**N Büyükpamukçu**, Department of Pediatric Surgery, Hacettepe University Faculty of Medicine

**M Çağlar, G Kale**, Department of Pediatric Pathology, Hacettepe University Faculty of Medicine

**Ü Çalışkan**, Department of Pediatrics, Selçuk University Faculty of Medicine, Konya, Turkey

Correspondence to: Dr S Emir, 58.sokak 41/6 Emek, 06510 Ankara, Turkey; emirs@ttnet.net.tr

Accepted 30 July 2002

## REFERENCES

- 1 Lin JJ, Lin F. Two entities in angiolipoma. A study of 459 cases of lipoma with review of literature on infiltrating angiolipoma. *Cancer* 1974;**34**:720-7.
- 2 Gonzalez-Crussi F, Enneking WF, Aream WM. Infiltrating angiolipoma. *J Bone Joint Surg* 1966;**48**:1111-23.
- 3 Hatley RM, Sabio H, Howell CG, *et al*. Successful management of an infant with a giant hemangioma of the retroperitoneum and Kasabach-Merritt syndrome with a  $\alpha$ -interferon. *J Pediatr Surg* 1993;**28**:1356-9.
- 4 White CW, Wolf SJ, Korones DN, *et al*. Treatment of childhood angiomatous diseases with recombinant interferon alfa-2a. *J Pediatr* 1991;**118**:59-66.
- 5 Ricketts RR, Hatley RM, Corden BJ, *et al*. Interferon-alpha-2a for the treatment of complex hemangiomas of infancy and childhood. *Ann Surg* 1994;**219**:605-14.
- 6 Bielenberg DR, Bucana CD, Sanchez R, *et al*. Progressive growth of infantile cutaneous hemangiomas is directly correlated with hyperplasia and angiogenesis of adjacent epidermis and inversely correlated with expression of the endogenous angiogenesis inhibitor, IFN-beta. *Int J Oncol* 1999;**14**:401-8.