

PostScript

LETTERS

If you have a burning desire to respond to a paper published in *ADC* or *F&N*, why not make use of our "rapid response" option?

Log on to our website (www.archdischild.com), find the paper that interests you, click on "full text" and send your response by email by clicking on "submit a response".

Providing it isn't libellous or obscene, it will be posted within seven days. You can retrieve it by clicking on "read eLetters" on our homepage.

The editors will decide, as before, whether to also publish it in a future paper issue.

Scimitar syndrome as a differential diagnosis in a child with recurrent wheeze

Respiratory symptoms of cough, wheeze, and breathlessness account for 40% of referrals to a general paediatric clinic. The majority of these children suffer from "wheeze secondary to upper respiratory tract infection" and "asthma".

A 7 year old girl was referred by her general practitioner to the clinic with a two month history of persistent cough and recurrent wheeze; she had been treated for suspected asthma with fluticasone and salbutamol since early childhood. There was a history of infantile eczema. She was growing well on the 50th centile. General examination was normal. There was no cyanosis or clubbing. Respiratory and cardiovascular system examinations were unremarkable.

She had been admitted at the age of 14 months with cough and wheeze; chest x ray showed right lower lobe consolidation which improved on antibiotics. Both radiographs were studied and the pattern of curvilinear density (scimitar) in the right lower zone suggestive of scimitar syndrome was recognised. She was referred to the paediatric cardiology department for echocardiography, which showed dilated right atrium, right ventricle, and a branch of the right pulmonary vein draining into the inferior vena cava, a mild variant of scimitar syndrome.

A cardiac catheterisation and coil embolisation of the systemic pulmonary collateral from the descending aorta to the right lower lobe is scheduled.

Scimitar syndrome is a name given to the triad of: (1) curvilinear vascular density in the right lower zone; (2) hypoplastic right lung; and (3) dextroposition of the heart. It has a wide spectrum of presentation and may sometimes only present in adulthood with symptoms of wheeze, recurrent chest infections, or pulmonary hypertension.¹

It remains a notoriously difficult diagnosis to make without a strong index of suspicion. In this case, pattern recognition on chest radiograph helped us to suspect the diagnosis. Examination and ECG may be entirely normal or just show right sided strain. Echocardiogram may also be normal or show dilated

right sided chambers (as in this case). Diagnosis can be missed in up to 33% cases by echocardiography.² More sensitive tests would include computed tomography scan, cardiac catheterisation, and magnetic resonance imaging with 3D MRA.^{3,4} Obstructive and early symptomatic types will usually need corrective surgery after stabilisation.⁵ Milder scimitar variant will probably do well with occlusion of the collateral supply.⁵

We have presented this case to highlight the fact that one has to keep an open mind regarding the final diagnosis in any child with recurrent wheeze, as all wheezes are not "asthma".

P R Desai, M Babu

Department of Paediatrics, St John's Hospital, Chelmsford CM2 9B, UK; prpravin@yahoo.com

References

- 1 Najm HK, Williams WG, Coles JG, et al. Scimitar syndrome: twenty years' experience and results of repair. *J Thorac Cardiovasc Surg* 1996;112:1161-8.
- 2 Wong ML, McCrindle BW, Mota C, et al. Echocardiographic evaluation of partial anomalous pulmonary venous drainage. *J Am Coll Cardiol* 1995;26:503-7.
- 3 Baran R, Kir A, Tor MM, et al. Scimitar syndrome: confirmation of diagnosis by a noninvasive technique (MRI). *Eur Radiol* 1996;6:92-4.
- 4 Huebsch P, Neuhold A, Mayr H, et al. Anomalous pulmonary venous drainage shown by duplex sonography, computed tomography, and plain radiography. *Thorax* 1989;44:63-5.
- 5 Dupis C, Charaf LAC, Breviere GM, et al. Infantile form of scimitar syndrome with pulmonary hypertension *Am J Cardiol* 1992;70:502-7.

Assessment of acute admissions by middle grade trainees and consultants will reduce the need for overnight hospital admissions

We carried out an audit to assess the impact on hospital admissions of patients being assessed by either middle grade trainees (residents) or consultants in a district general hospital (DGH). Our aims were to establish:

- Number of children kept in hospital overnight and those discharged the same day
- Number of readmissions of those discharged the same day
- Any adverse events in those discharged home the same day.

We studied retrospectively all acute admissions to the children's wards at Doncaster Royal Infirmary, a medium sized district general hospital, over the months of January and July 1998. We excluded all surgical and non-acute admissions. At the time of the study the Children's Hospital did not have a day or acute assessment unit. Therefore the children were reviewed following admission to the wards. Whether trainees or consultants reviewed patients was an entirely random process, dependent on willingness and time to carry out ward rounds in late afternoon or early evening. The review could also be triggered by nursing staff or parents. The interval between the time of admission to the ward and the time the patients were reviewed varied from immediate review to a few hours. The decision to discharge children was usually taken jointly by medical and nursing staff, provided that parents were willing to look after their children at home. The parents of children discharged home on the same day as admission were given open access to the children's ward—that is, they could either telephone the ward for advice or return with the child if concerned.

A total of 512 sets of case notes were reviewed by MMM and RAS. A pro forma was used to collect the data, which was stored on an Excel spreadsheet.

A total of 173 (34%) patients were under 1 year, 150 (29%) were 1-2 years, 53 (10%) were 3-4 years, 41 (8%) were 5-6 years, and 95 (18%) were over 6 years (fig 1). The source of referral was documented in 499 case notes. Of these, 287 (58%) were via a general practitioner, 178 (36%) were via the accident and emergency department, and 29 were from other sources. The commonest reason for admission was breathing difficulties followed by fever.

Of the 512 patients admitted, 260 (51%) were reviewed by middle grade trainees or consultants. Of those reviewed, 109 (42%)

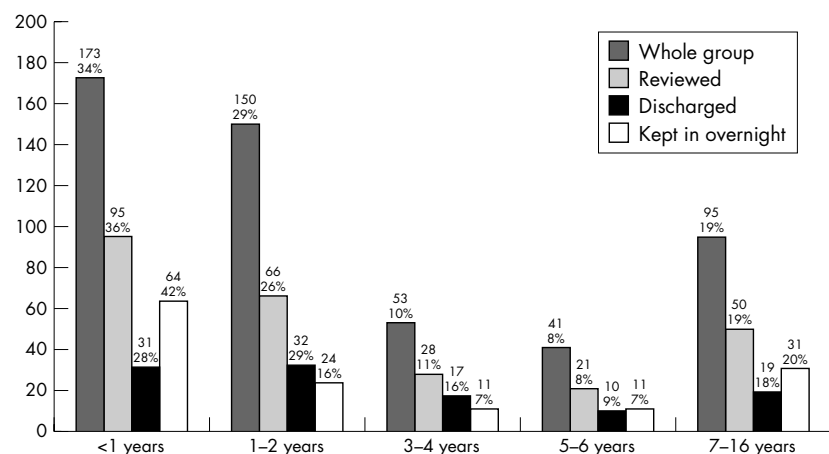


Figure 1 Breakdown of age groups.

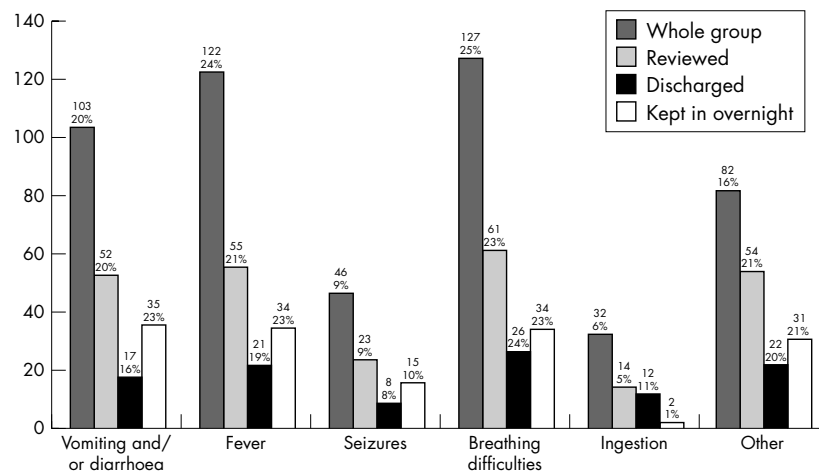


Figure 2 Reason for admission.

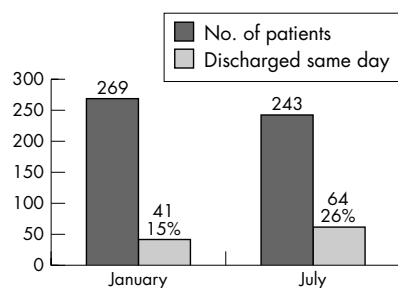


Figure 3 Number of patients discharged.

were discharged home the same day. The age group distribution (fig 1) and reason for admission (fig 2) of those reviewed was similar to that of the total sample. More children under 1 year were kept in overnight than were discharged home the same day; the reverse was true for those in the 1–2 year and 3–4 year age groups. The reason for admission of those discharged home the same day was also similar to that of the total sample. Slightly more patients were admitted in January than in July, but more patients were discharged home the same day in July than in January (26% v 15%; fig 3). This could well be due to the fact that there is more pressure on beds in the winter months. However, it could also be due to a different spectrum and severity of diseases.

Of those discharged home the same day, seven (6%) were readmitted within seven days, four because of the same complaint and three with a different complaint. There were no adverse events. Those who were reviewed but kept in overnight had a similar distribution of the reason for admission to that of the total sample and those who were reviewed but with an excess of vomiting and/or diarrhoea.

In conclusion, assessing the need for admission resulted in 20% of all admissions (40% of those reviewed) being discharged home the same day. Vomiting and/or diarrhoea were more likely to result in patients being kept in overnight. We believe the number of patients who can be discharged home the same day will be much higher if all acute admissions are reviewed and assessed in the way described. This policy seems safe and acceptable to parents.

With the planned reduction in the number of specialist registrars, it seems that expanding the number of consultants would achieve

the dual benefit of moving closer towards a consultant provided service and will also lead to reduction in the number of children requiring an overnight hospital admission.

M M Madlom, R Singh

Doncaster and Bassetlaw NHS Trust, The Children's Hospital, Doncaster Royal Infirmary, Armthorpe Road, Doncaster DN2 5LT, UK; madlom@hotmail.com

A S Rigby

Division of Child Health, Sheffield Children's Hospital, Western Bank, Sheffield, UK

Parkinson-like syndrome as the major presenting symptom of Epstein-Barr virus encephalitis

The main symptoms of Epstein-Barr virus encephalitis (EBV) encephalitis are fever, seizure, bizarre behaviour, headache, and metamorphosis.¹ Bradykinesia, akathisia, involuntary hand movements, drooling, and torticollis are symptoms of Parkinson-like syndrome, which has never been described as a manifestation of EBV encephalitis. We report the case of a previously healthy boy who presented with Parkinson-like syndrome as the major symptom of EBV encephalitis.

A 12 year old, previously healthy boy was referred to our hospital because of severe cough with sputum and intermittent fever for seven days. Abdominal discomfort and vomiting were also noted one day before admission. On admission, his consciousness was clear with no focal neurological sign, no hepatosplenomegaly, no lymphadenopathy, and no exudative tonsillitis or skin rash. There was no

previous personal or family history of seizure disorder or migraine, and both the boy and his family denied being exposed to some possible hallucinogenic or neuroleptic drug. Blood analysis was normal except for a mild leucocytosis with a left shift (10 500/mm³; 84.6% neutrophils), and there were no atypical lymphocytes. C reactive protein (CRP) level was 0.17 mg/dl (normal <0.3 mg/dl).

After admission, mucolytic agents and bronchodilators were prescribed. Fever, abdominal discomfort, and vomiting subsided soon. Twenty four hours after admission, his condition deteriorated with drowsiness, involuntary rhythmic finger tapping movement, resting tremor, bradykinesia, photophobia, and staring eyes. But perceptual distortion was not noted. Cerebrospinal fluid (CSF) examination yielded yellow, clear fluid and normal opening pressure without microorganisms on Gram stain or culture. The cell count, protein, and sugar of CSF were all within normal limits. Table 1 lists laboratory evaluations for EBV and other possible pathogens of encephalitis. Brain magnetic resonance imaging (MRI) showed no abnormalities. Tc-99m HMPAO brain SPECT (Tc-99m hexamethylpropyleneamine oxime single photon emission tomography) showed diminished perfusion in the region of the right caudate nucleus. Electroencephalography (EEG) revealed diffuse slowing of background activity. His signs and symptoms showed gradual improvement under close observation in the following three weeks. He was then discharged in a stable condition. Follow up four months later showed no residual neurological sequelae.

Parkinson-like syndrome (extrapyramidal symptoms) is characterised by various neurological symptoms including akathisia, bradykinesia, torticollis, drooling, and involuntary hand movement. This syndrome develops in at least a quarter of children treated with neuroleptics due to disruption of the balance between the dopaminergic system and the cholinergic system within the basal ganglia. But Parkinson-like syndrome has also been recognised as a sequela of acute viral encephalitis, including coxsackie B, cytomegalovirus, measles, herpes simplex virus, Japanese B encephalitis virus, and encephalitis lethargica. *Mycoplasma pneumoniae* infection has also been recognised as a cause of Parkinson-like syndrome.² In our patient, exposure to possible hallucinogenic or neuroleptic drugs was denied. Serological tests and culture for other possible pathogens were negative. EBV encephalitis was diagnosed by serological and CSF polymerase chain reaction findings which fulfilled the diagnostic criteria.

EBV encephalitis is generally considered to be a benign, self limited disease associated with few sequelae. However, an incidence of

Table 1 Serological evidence for EBV encephalitis

	Day 1	Day 14
EBV VCA-IgM	1/32 (positive)	
EBV VCA-IgG	1/160	1/640
EBV determined nuclear antigens	Negative	
EBV CSF PCR	Positive	
<i>Mycoplasma pneumoniae</i> IgM	<1/40	<1/40
Culture for enterovirus	Negative	Negative
Coxsackie B virus IgM	Negative	
Cytomegalovirus IgM	Negative	
Herpes simplex IgG and IgM	Negative	
JBE virus IgM	Negative	

neurological sequelae after EBV encephalitis as high as 36% was reported by Domachowski and colleagues.³ The present case, therefore, not only draws attention to the role of EBV in infectious neurological disorders, but also suggests that an EBV aetiology should be considered in cases of Parkinson-like syndrome in childhood.

J-C Hsieh, K-H Lue, Y-L Lee

Chung Shan Medical University Hospital,
23 Sec. 1 Taijunggang road, Shi Chiu, Taichung,
Ta, Republic of China; kent0837@yahoo.com.tw

References

- 1 **Hung KL**, Liao HT, Tsai ML. Epstein-Barr virus encephalitis in children. *Acta Paediatr TW* 2000;**41**:140–6.
- 2 **Smith R**, Eviatar L. Neurologic manifestations of *Mycoplasma pneumoniae* infections: diverse spectrum of diseases. *Clin Pediatr* 2000;**39**:195–201.
- 3 **Domachowski JB**, Cunningham CK, Cummings DL, *et al.* Acute manifestations and neurologic sequelae of Epstein-Barr virus encephalitis in children. *Pediatr Infect Dis J* 1996;**15**:871–5.

Hyperextension of spine: unusual presentation of Guillain-Barré syndrome

Guillain-Barré syndrome (GBS) classically presents as ascending symmetric areflexic weakness with positive sensory symptoms. Recently, we managed a child presenting with unusual posture and hyperextension of the whole spine.

A 9 year boy presented with inability to hold books and write, and a limp. Over 12 hours he had developed tingling sensations and pain in the calf muscles; pain progressed to involve the neck and back by 24 hours and he was unable to flex his neck and extend his limbs. During the next two days weakness increased, especially of the lower limbs. By day 4, he had developed hyperextension of the cervical and thoracolumbar spine with flexed and adducted limbs. On day 6 when he

presented to us, vital signs including blood pressure were normal and remained so during the hospital stay. He had painful restriction of passive extension at all joints; motor power and tone could not therefore be assessed. He had bilateral symmetrical weakness: shoulders (abductor, adductor, 2/5), elbows (flexor 3/5, extensor 2/5), wrists (dorsiflexor, palmarflexor, 2/5), finger flexors (2/5), hand grip (20–30%), hip flexors (2/5), knees (flexor, extensors, 2/5), ankle (0/5), toes (0/5). Deep tendon reflexes were absent except for the biceps, which also disappeared by day 12. Cremasteric and abdominal reflexes were present; plantars were absent bilaterally. The spine was normal except for hyperextension of the cervical and thoracolumbar region. Respiratory muscles, higher mental functions, speech, cranial nerves, and bowel and bladder functions were normal. A plain radiograph of the spine showed mild thoracic lordosis. Cerebrospinal fluid examination on day 11 showed high protein (95 mg/dl). On day 12, spinal hyperextension and abnormal limb postures disappeared following improvement in pain as a result of analgesic therapy. Kernig's and Brudzinski's signs could be elicited. Lasegue's sign¹ and the straight leg raising test were also positive. Symmetrical hypotonia became obvious.

GBS was suspected in view of progressive bilateral symmetrical weakness, severe radiculopathy, and albumino-cytological dissociation.² Nerve conduction studies, performed on day 23, showed reduced nerve conduction velocity in the motor nerves. Sensory nerves were normal. We could not determine F wave conduction velocity. The pain and tenderness subsided gradually. With regular physiotherapy the neck became soft, motor power improved, and he was able to sit unsupported by day 20. Four months later, neurological examination was normal. A stool culture for poliovirus was negative.

Children with GBS frequently have pain in the back and lower limbs, which is aggravated on the straight leg raising test in most of them.³ These pain syndromes are attributable

to radiculitis,⁴ an early and predominant feature in GBS.³ Prominent radiculitis in this case might have led to severe pain in the back, causing generalised paravertebral muscle spasm. This resulted in the unusual posture of hyperextension of the spine.

A K Baranwal, S C Singhi

Department of Pediatrics, BP Koirala Institute of Health Sciences, Dharan, Nepal; baranwal1970@yahoo.com

REFERENCES

- 1 **Oosterhuis HJ**. Physical diagnosis—signs of lumbosacral irritation [in Dutch]. *Ned Tijdschr Geneesk* 1999;**143**:617–20.
- 2 **Asbury AK**, Cornblath DR. Assessment of current diagnostic criteria for Guillain-Barre syndrome. *Ann Neurol* 1990;**27**(suppl):S21–4.
- 3 **Nguyen DK**, Agenarioti-Belanger S, Vanasse M. Pain and the Guillain-Barre syndrome in children under 6 years old. *J Pediatr* 1999;**134**:773–6.
- 4 **Cull RE**. The nervous system. In: Munro JF, Edwards CRW, eds. *Macleod's clinical examinations*. Edinburgh: Churchill Livingstone, 1990:187–254.
- 5 **Lebrun C**, Ghetau G, Candito M, *et al.* Acute polyradiculoneuritis and dysautonomia: contribution of assaying catecholamines and their methoxylated metabolites. *Rev Neurol (Paris)* 2001;**157**:304–8.

CORRECTIONS

An error occurred in the letter by S Ashraf and M Z Mughal in the September issue (*Arch Dis Child* 2002;**87**:263–4). In the fifth paragraph, the first sentence should read “According to the 1991 census data there were approximately 4000, 6–36 month old children of ethnic minority background resident in the city of Manchester.” The journal apologises for the error.

The photograph of children in the Morigata area in Delhi on the cover of the August issue was taken by the American photographer Mark Duerksen of Dallas, Texas.