

Basal ganglia infarction associated with HHV-6 infection

David W Webb, Bruce H Bjornson, Michael A Sargent, Juliette Hukin, Eva E Thomas

Abstract

A 6 year old boy presented with meningoencephalitis and was found to have serological evidence of acute human herpes virus-6 (HHV-6) infection. He did not develop symptomatic seizures or the rash of exanthum subitum (roseola). His course was marked by severe spastic quadriparesis associated with radiological evidence of basal ganglia infarction. HHV-6 infection should be considered in any child with acute meningoencephalitis.
(*Arch Dis Child* 1997;76:362-364)

Keywords: human herpes virus-6; meningoencephalitis; neurological sequelae

Primary infection with human herpes virus-6 (HHV-6) occurs predominantly in early childhood and presents as a self limiting febrile illness with or without the rash of exanthem subitum (roseola).¹ HHV-6 is associated with early febrile seizures and is a potential cause of meningoencephalitis in childhood.¹ We report a child with HHV-6 infection who developed unexpectedly severe neurological sequelae.

Case report

A 6 year old boy was admitted with a two day history of increasing drowsiness and a seven day history of sore throat, anorexia, and low grade fever. Three days before admission he began vomiting and became lethargic. He had been previously healthy with normal development. His parents were unrelated and there was no family history of note. There had been no history of recent travel or insect bites.

On examination, axillary temperature was 38°C, pulse was 88/min, respiratory rate 22/min, and blood pressure 110/74. Weight was 19.7 kg (25th centile), height 122 cm (90th centile), and head circumference 52.5 cm (50th centile). There was no significant lymphadenopathy or rash, nor were there respiratory tract signs, murmurs, or visceromegaly. He had spontaneous eye opening but no verbal response. There were also some spontaneous limb movements and he was localising to deep pain but not obeying commands. The optic fundi were normal and pupils were equal and reactive but he did not fix or follow. Other brain stem reflexes were intact. He had severe neck rigidity and evidence of spastic quadriparesis, with symmetrical brisk deep tendon reflexes, bilateral clonus, and extensor plantar responses.

INVESTIGATIONS

Peripheral leucocyte count was $11.5 \times 10^9/l$ (lymphocytes $1.5 \times 10^9/l$). Serum glucose, electrolytes, calcium, creatinine, alanine aminotransferase, aspartate aminotransferase, bicarbonate, ammonia, and lactate were all normal. Erythrocyte sedimentation rate was 35 mm/hour. Urinalysis was unremarkable. Cranial computed tomography (without contrast) was normal. His cerebrospinal fluid (CSF) had 14 red cells and 189 nucleated cells with 81% lymphocytes, 2% neutrophils, and 17% monomacrophages. CSF glucose was 5.2 mmol/l, CSF:serum glucose ratio 0.5, protein 0.64 g/l, CSF lactate 1.4 mmol/l, and Gram stain negative.

Culture of throat swab, urine, blood, CSF, and stool proved negative for bacterial and viral pathogens. A CSF sample was negative for herpes simplex virus by polymerase chain reaction. Six serial blood samples were analysed for the presence of antiviral antibodies (table 1) and the results were compatible with a primary HHV-6 infection. IgM to herpes simplex, cytomegalovirus, and Epstein-Barr virus was negative. IgG concentrations were consistent with immunity to cytomegalovirus, varicella zoster, measles, mumps, and rubella virus. Complement fixation assay was negative for adenovirus and enteroviral infection. Assessment of immunological status including lymphocyte subsets was normal.

Cranial computed tomography on day 4 and 14 of his admission revealed increasing radiolucency of the right lentiform nucleus and atrophy of both caudate nuclei (fig 1A). Cranial magnetic resonance imaging three months later showed atrophy of the heads of caudate nuclei with symmetrical enlargement of the lateral and third ventricles associated with tissue loss (fig 1B).

CLINICAL COURSE

He remained unresponsive for five days and received intravenous cefotaxime and acyclovir. He developed clinical and biochemical evidence of anicteric hepatitis on day 10 of his admission and this resolved spontaneously. He had purposeful withdrawal of limbs to pain by day 10 but remained verbally unresponsive with evidence of a pseudobulbar palsy and a severe spastic quadriparesis. Five months after discharge, after a period of rehabilitative care, he is able to walk independently, dress with assistance, and feed himself. He is fully continent. He has dysarthria and mild left hemiparesis. Cogni-

British Columbia's
Children's Hospital,
Vancouver, BC,
Canada: Department
of Paediatric
Neurology
D W Webb
B H Bjornson
J Hukin

Department of
Radiology
M A Sargent

Department of
Pathology and
Laboratory Medicine
E E Thomas

Correspondence to:
Dr D W Webb, Royal Belfast
Hospital for Sick Children,
Falls Road, Belfast BT12
6BE.

Accepted 19 November 1996

Table 1 Acute and convalescent serology in a child with meningoencephalitis and HHV-6 infection

Time	Immunofluorescence assay		ELISA	
	HHV-6 IgM	HHV-6 IgG	HHV-6 IgM	HHV-6 IgG
Day				
3	1:20480	1:640		
10	1:10240	1:320	Positive	Positive
14	1:5120	1:320	Positive	Positive
14 (CSF)	1:40		Positive	Positive
Week				
6	1:5120	1:20		
11	1:640	Negative		
16	1:320	Negative		

ELISA = enzyme linked immunosorbent assay.

tive assessment revealed good abstract reasoning but significant difficulty with memory and fine motor skills. No seizures have been observed.

Discussion

The infrequent association of roseola with childhood encephalopathy has been noted by several authors and summarised by Burnstine and Paine in 1959.² Onset of central nervous system involvement was characteristically during the febrile period with prolonged seizures, followed by focal motor deficits of variable

outcome. Several children with HHV-6 associated encephalitis have now been reported,^{1 3-6} and are summarised in table 2. One child died and among the remainder three had early evidence of developmental delay. Information on long term follow up evaluation is not available.

The ability of HHV-6 to invade the brain has been documented by its identification in the brain of an immunosuppressed patient who died following meningoencephalitis.⁷ Infection of cerebral tissue was associated with both astrocyte depletion, demyelination, and neuronal destruction. White matter involvement was most marked in the frontal lobe while there was evidence of an asymmetric pattern of neuronal infection in the hippocampal gyrus and dentate nuclei. The presence of HHV-6 related structural proteins indicated that this infection was active as opposed to latent. Brain invasion appears to occur at an early stage of infection as the virus has been identified in the CSF during the acute stages of the illness but not later.⁵ Although intrathecal HHV-6 antibody production has been demonstrated by others,³ we could not demonstrate this in our case. An

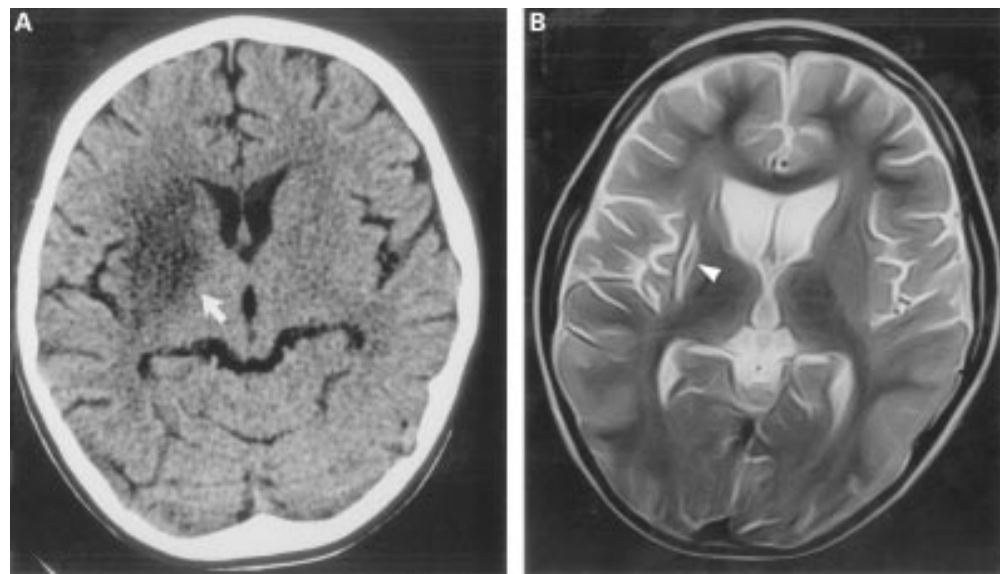


Figure 1 (A) Transverse axial computed tomogram on day 14 of his admission shows marked radiolucency in the right lentiform nucleus (arrow). (B) Transverse axial T2 weighted magnetic resonance imaging three months after admission shows atrophy of both caudate nuclei with enlargement of the adjacent lateral ventricles. The right putamen is small (arrowhead) and shows focal hyperintensity which could be due to methaemoglobin or early calcification.

Table 2 Summary of clinical, laboratory, and neuroimaging studies in children reported to have meningoencephalitis associated with HHV-6 infection

Age*	Sex	Seizures†	CSF			Cranial computed tomography radiolucency	Reference No
			Leucocytes (cells/mm ³) (% lymphocytes)	Protein (g/l)	Glucose		
10m	M	+	36	2.94	Not reported	Putamen, external capsule	3
13m	F	+	15 (93)	1.6	Normal	Left frontotemporal	1
10m	F	+	Normal	Normal	Normal	Left frontoparietal	4
9m	F	++	28 (76)	0.66	Normal	Left frontotemporal	5
9m	F	++	Normal	Normal	Normal	Diffuse (died)	5
13m	F	+	14 (96)	0.57	Normal	Bitemporal	5
8m	F	+	28 (85)	Not reported	Normal	Left frontal	5
22m	M	++	4	Normal	Normal	Normal	6
6y	M	—	189 (81)	0.64	Normal	Basal ganglia	(our case)

* Age in months (m) or years (y).

† ++ Status epilepticus.

alternative explanation is that children with severe cerebral destruction without virus isolation represent cases of immune mediated encephalomyelitis.

HHV-6 associated meningoencephalitis is not exclusively a disease of infants and may not be associated with symptomatic seizures or the rash of exanthum subitum (roseola). The acute illness may be complicated by neurological sequelae including involvement of the basal ganglia. HHV-6 infection should be considered in any child presenting with an unexplained meningoencephalitis.

We would like to thank Dr Rob Wishart and Dr Marilyn Unger for providing helpful clinical information and Ms Fiona Flemming for her help in preparing the manuscript. Reprints will not be provided.

- 1 Irving WL, Chang J, Raymond DR, Dunstan R, P Grattan-Smith, Cunningham AL. Roseola infantum and other syndromes associated with acute HHV-6 infection. *Arch Dis Child* 1990;65:1297-300.
- 2 Burnstine RC, Paine RS. Residual encephalopathy following roseola infantum. *Am J Dis Child* 1959;98:144-52.
- 3 Ishiguro N, Yamada S, Takahashi T, et al. Meningoencephalitis associated with HHV-6 related exanthem subitum. *Acta Paediatric Scand* 1990;79:987-9.
- 4 Gloning H, Stettner-Gloning R, Pontz BF, Emmrich P. [Exanthem subitum, encephalopathy, and hepatitis caused by human herpes virus type 6 in a 10 month old infant]. *Monatsschrift Kinderheilkunde* 1991;139:297-300.
- 5 Suga S, Yoshikawa T, Asano Y, et al. Clinical and virological analyses of 21 infants with exanthem subitum (roseola infantum) and central nervous system complications. *Ann Neurol* 1993;33:597-603.
- 6 Jones CMV, Dunn HG, Thomas EE, et al. Acute encephalopathy and status epilepticus associated with human herpes virus-6 infection. *Dev Med Child Neurol* 1994;36:646-50.
- 7 Drobyski WR, Knox KK, Majewski D, Carrigan DR. Fatal encephalitis due to variant B human herpes virus-6 infection in a bone marrow transplant recipient. *N Engl J Med* 1994;330:1356-60.