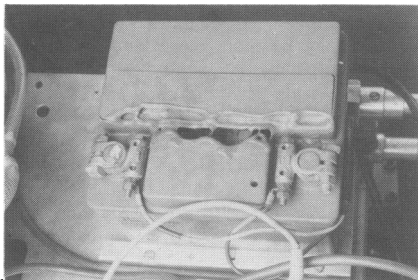


about 75 babies annually. Recently an experienced team were collecting an extremely sick baby with pulmonary hypoplasia who required maximal support and monitoring. The baby was transferred to the transport incubator before departure and a pulse oximeter was inadvertently placed on top of the 12 volt car battery used to power the incubator. Sparks and flames ensued, which were extinguished by a quick thinking senior house officer using a carbon dioxide fire extinguisher. The accident would obviously have been much worse if the team had left the hospital.

On close inspection afterwards the metal terminals of the battery were found to be exposed (figure). Current had passed through the casing of the pulse oximeter which still worked. The plastic coverings originally supplied with the battery had long since been mislaid. We report this incident as we feel that other units with old transport systems may also have lost the battery coverings, and suggest that the batteries used to power incubators should be completely encased. Consideration might also be given to inclusion of a fire extinguisher in the flying squad equipment.

JANET M RENNIE
ED BROADHURST
Rosie Maternity Hospital,
Robinson Way,
Cambridge CB2 2SW



Exposed terminals and damage to battery.

Treating neonatal jaundice with phenobarbitone: the inadvertent administration of significant doses of ethyl alcohol

SIR,—One indication for the administration of phenobarbitone is neonatal jaundice: the drug acts on the immature liver to induce microsomal enzymes and may also have a direct protective effect on the central nervous system.

Phenobarbitone can be given orally as an elixir. The hospital pharmacy will prepare this, on request, as an aqueous solution. In this form, the elixir keeps poorly and cannot be stored on the ward. Stock phenobarbitone elixir on the ward, however, is made with ethyl alcohol to prolong its shelf life. Elixirs in this form are purchased directly from the drug companies and are 40% ethyl alcohol by volume.¹

Regular dosing with the alcoholic elixir can result in neonatal alcohol toxicity. It should not be taken for granted that the elixir will be aqueous. We would therefore advise that the solvent is also specified on the drug chart when prescribing oral phenobarbitone elixir for neonatal jaundice.

W COLQUHOUN-FLANNERY
R WHEELER
Wessex Regional Centre
for Paediatric Surgery,
Southampton General Hospital,
East Wing, Shirley,
Southampton SO9 4XY

1 *The EBL guide*. Aylesbury: Edwin Burgess, 1988:178.

Dr Leach comments:

Drs Colquhoun-Flannery and Wheeler are perfectly correct in saying that elixir phenobarbitone contains high amounts of alcohol: the current preparation included in the *British National Formulary* (September 1991) contains 'phenobarbitone 15 mg/5 ml in a suitable flavoured vehicle, containing alcohol 38%'. The current edition of *The Extra Pharmacopoeia* (29th edition, 1989) includes phenobarbitone elixir BP (phenobarbitone oral solution) and states that it is a solution containing phenobarbitone 0.3% and alcohol 38%—that is, the same formulation as the elixir in the *British National Formulary*.

Phenobarbitone has only a low solubility in water (1 in 1000) but is soluble in alcohol (1 in 10). It is therefore necessary to include a high proportion of alcohol in the formulation to achieve adequate solution of the phenobarbitone. An aqueous preparation would require the use of phenobarbitone sodium which is water soluble.

FRANK LEACH
North Western Regional Health Authority,
Regional Drug Information Service

Parenteral lipids and free radicals in preterm infants

SIR,—Professor Cooke describes an interesting association between the use of parenteral lipids and chronic lung disease in preterm infants.¹ The study nicely confirms and extends the results of Hammerman and Aramburo.² The author mentions lipid peroxidation and generation of free radicals in the lipid solution as one possible mechanism by which parenteral lipid solutions may injure preterm infants.¹ We should like to draw your readers' attention to the following: free radical induced lipid peroxidation in parenteral lipid solution has actually been described both in vitro and in vivo upon infusion in preterm infants.^{3,4} Although the article referred to by the author does not concern lipid peroxidation and free radicals,⁵ we agree with Professor Cooke's conclusion that the advantages of parenteral lipid infusion should be carefully weighed against its potential for harm. The possibility of such adverse effects should not be ignored, particularly when using parenteral nutrition in small premature infants. Work with these patients indicates a close association between free radical induced lipid peroxidation and chronic lung disease.⁶

STURE ANDERSSON
OLLI PITKANEN
Children's Hospital,
00290 Helsinki, Finland

MIKKO HALLMAN
University of California,
Irvine, CA 92668, USA

- 1 Cooke RWI. Factors associated with chronic lung disease in preterm infants. *Arch Dis Child* 1991;66:776-9.
- 2 Hammerman C, Aramburo MJ. Decreased lipid intake reduces morbidity in sick premature infants. *J Pediatr* 1988;113:1083-8.
- 3 Whispe JR, Bell EF, Roberts RJ. Assessment of lipid peroxidation in newborn infants and rabbits by measurements of expired ethane and pentane: influence of parenteral lipid infusion. *Pediatr Res* 1985;19:374-9.
- 4 Pitkanen O, Hallman M, Andersson S. Generation of free radicals in lipid emulsion used in parenteral nutrition. *Pediatr Res* 1991;29:56-9.

- 5 Pereira GR, Fox WW, Stanley XA, Baker L, Schwartz JG. Decreased oxygenation and hyperlipemia during intravenous fat infusions in premature infants. *Pediatrics* 1980;66:26-30.
- 6 Pitkanen OM, Hallman M, Andersson SM. Correlation of free oxygen radical-induced lipid peroxidation with outcome in very low birth weight infants. *J Pediatr* 1990;116:760-4.

Antenatal diagnosis of inborn errors of metabolism

SIR,—The authors of this paper state that they are unaware that prenatal diagnosis has been attempted for hyperlysinemia.¹ After the diagnosis of a previously affected child such an attempt has been made in a subsequent pregnancy.² The presence of an unaffected fetus was demonstrated by normal amniotic fluid amino acid analysis and normal oxidation of lysine by cultured amniotic fluid cells. Thereafter, the parents refused further attempts at antenatal diagnosis and three affected infants were born, the management of whom has been reported in this journal.³

J W GREGORY
Department of Child Health,
The Medical School,
Framlington Place,
Newcastle upon Tyne NE2 4HH

- 1 Cleary MA, Wraith JE. Antenatal diagnosis of inborn errors of metabolism. *Arch Dis Child* 1991;66:816-22.
- 2 Gray RGF, Bennett MJ, Green A, et al. Studies on a case of persistent hyperlysinemia with a possible method for prenatal diagnosis. *J Inherited Metab Dis* 1983;6(suppl 2):115-6.
- 3 Gregory JW, Beail N, Boyle NA, Dobrowski C, Jackson P. Dietary treatment of hyperlysinemia. *Arch Dis Child* 1989;64:716-20.

Transient gluten intolerance

SIR,—Burgin-Wolff *et al* report that 11% of children (15/134) who were originally diagnosed as having coeliac disease, with a flat small intestinal mucosa and clinical response to a gluten free diet, had a normal small intestinal mucosa after four to 15 years of regular gluten challenge.¹ Thus there had been no histological or clinical relapse after this interval making it possible that the original diagnosis in these children was transient gluten intolerance rather than coeliac disease. None the less Polanco and Larrauri have reported five children with coeliac disease who took up to nine years to relapse after gluten challenge having been shown to have normal small intestinal mucosal biopsies four to five years after gluten challenge.² Thus some of the children reported by Burgin-Wolff *et al* may ultimately relapse. Nevertheless it is of great importance that all 15 children who have not relapsed were aged less than 2 years at initial diagnosis. This finding provides firm data to support the revised European Society for Paediatric Gastroenterology and Nutrition (ESPGAN) criteria for coeliac disease³ recommendation that children originally diagnosed as coeliac disease under the age of 2 years should always have the diagnosis established by means of serial biopsies coupled with gluten elimination and challenge as originally recommended.⁴ No child over this age failed to relapse in the study of Burgin-Wolff *et al*.

What still remains unknown is the gamma-delta status of the intraepithelial lymphocytes of biopsy specimens from children diagnosed as having transient gluten intolerance.