

Original articles**Ciliary abnormalities in respiratory disease**

R M BUCHDAHL, J REISER, D INGRAM, A RUTMAN,* P J COLE,* AND J O WARNER

*Paediatric Respiratory Department, Brompton Hospital and the *Host Defence Unit, Department of Thoracic Medicine, Cardiothoracic Institute, London*

SUMMARY One hundred and sixty seven children, ranging in age from 5 weeks to 16 years, with chronic upper or lower respiratory tract problems, or both, were investigated for ciliary dyskinesia. Abnormal ciliary function was found in 18 cases all of whom had chronic lower respiratory disease and most of whom also had upper respiratory problems. Fifteen of the 18 cases had reduced ciliary beat frequencies (<10 Hz) associated with dyskinesia and the other three showed apparent absence of ciliated cells. Of the 15 cases with reduced ciliary beat frequencies, ciliary ultrastructure was normal in seven cases but abnormal with missing dynein arms and occasional abnormalities of microtubular arrangement in eight. Respiratory symptoms in the perinatal period were more common in children with abnormal ciliary function and present in all those with ultrastructural abnormalities or absence of ciliated cells compared with 34 (26%) of 132 children, in whom symptoms were recorded, with normal ciliary function.

This study would suggest that all children with unexplained chronic respiratory disease, in particular those with symptoms starting in the perinatal period, should be investigated for ciliary dyskinesia.

Primary ciliary dyskinesia, or the immotile cilia syndrome, was first described in association with Kartagener's syndrome (situs inversus, bronchiectasis, and sinusitis).¹ The condition is thought to be inherited in an autosomal recessive manner and to affect 1 in 15 000 people.² Impaired ciliary function is thought to result from absence of the dynein arms that are normally attached to the outer microtubular doublets within the cilia (fig 1). Reduced ciliary motility causes reduction in mucociliary clearance and predisposition to infection throughout the respiratory tract. In addition, it is speculated that the abnormality disturbs the normal developmental symmetry of vital organs resulting in random laevo or dextroposition of such organs as the heart, liver, and spleen.¹ Affected males are usually infertile because their sperm, being of similar structure to cilia, are poorly motile or non-motile.

More recently it has become apparent that there is a wider pattern of ciliary abnormalities than was originally recognised. Ultrastructural abnormalities range from the complete absence of dynein arms to partial absence affecting the outer or inner arms only. Microtubules may be rearranged or lost and transposition or duplication anomalies can occur.³ Ciliary ultrastructure may be normal despite im-

paired function as defined by a reduction in ciliary beat frequency,⁴ and there are reports of ciliary aplasia occurring throughout the respiratory tract.^{5,6}

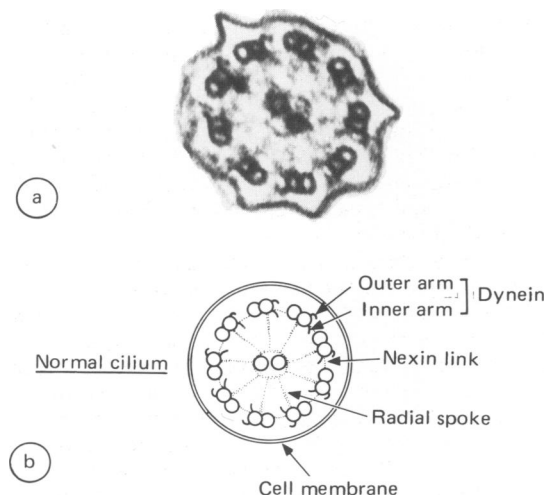


Fig 1 (a) Electron micrograph (magnification $\times 100\ 000$) and (b) schematic drawing (courtesy of A Dewar) of transverse section of a normal cilium.

In addition, ciliary dyskinesia may be secondary to viral or bacterial infection, returning to normal with appropriate treatment and time.⁷⁻¹⁰ Respiratory problems associated with ciliary dyskinesia are well recognised in childhood, indeed the diagnosis should be considered in any neonate or infant with unexplained respiratory distress.^{11 12}

Since April 1985 it has been our policy to include examination of ciliary function as part of the routine procedure for investigating children with chronic upper and lower respiratory tract disease of unknown aetiology and we report the results of testing 167 children over a 26 month period.

Patients and methods

One hundred and sixty seven children (79 girls and 88 boys; age range 5 weeks to 16 years) were studied between April 1985 and May 1987. Most had either recurrent or chronic upper or lower respiratory symptoms, or both, of more than one month's duration. Five asymptomatic siblings of affected children were also investigated. In most cases examination of ciliary function was performed together with other investigations: these included a chest radiograph to determine the cause and extent of lower respiratory tract disease and organ situs.

In vitro examination of ciliary function was performed by a photometric technique¹³ measuring ciliary beat frequency with automated recording.¹⁴ A sample of ciliated epithelium was obtained from the inferior turbinate of the nose using a cytology brush without anaesthesia.¹³ The cilia were suspended in 2 ml of medium 199 cell culture fluid (Flow Laboratories) and a small sample examined in a sealed microscope slide-coverslip chamber. The preparation was placed on an electronically controlled warmstage (Microtec) at 37°C and allowed to equilibrate for several minutes. Providing there were two or more strips of intact ciliated epithelium present measurement of ciliary beat frequency could be performed. If there were fewer than two strips of ciliated epithelium a second nasal brushing was performed. Occasionally epithelial strips were found with disrupted ciliated borders or with absent cilia and associated with the presence of mucopurulent material. In these cases the child was prescribed a course of systemic antibiotic and topical nasal antibiotic with corticosteroid drops and the brushing repeated several weeks later. Ciliary movement was inspected and ciliary beat frequency measured on a Leitz Dialux 20 phase contrast microscope at a magnification of 320. The cilia were positioned to interrupt a passage of light through a small diaphragm into a Leitz MPV compact microscope photometer. This converted light intensity into an

electrical signal that was subsequently read as a ciliary beat frequency in Hz using a ciliary beat frequency processor unit. At least three readings of beat frequency were made on at least two strips of ciliated epithelium and a mean value calculated. Where cilia were present with a mean ciliary beat frequency of less than 10 Hz a second brushing for ultrastructure was performed and the cilia immediately fixed in 2.5% glutaraldehyde in cacodylate buffer and then postfixed in 1% osmium tetroxide. After agar embedding and Araldite infiltration sections were cut and examined by light and transmission electron microscopy.¹⁵

A normal range for ciliary beat frequency in the age range studied has not been obtained (for ethical reasons), but there seems to be no variation with age in normal adults. In our laboratory the ciliary beat frequency in normal adults is usually found to be in the range of 12 to 15 Hz in comparison with subjects with primary ciliary dyskinesia associated with Kartagener's syndrome where the frequency is usually less than 10 Hz.¹⁶ We have therefore considered any ciliary beat frequency of less than 10 Hz to be appreciably abnormal.

Results

Children were referred with a wide range of respiratory problems as listed in table 1. The five asymptomatic children, the near-miss cot death, and the child with obstructive apnoea all had normal ciliary function.

Eighteen children were found to have either low ciliary beat frequency with abnormal ciliary ultrastructure (eight cases), low ciliary beat frequency

Table 1 Main clinical indications for referral. (No of children=167)

Indication	No of cases (%)
Lower respiratory tract problems	
Pneumonia/chest infection	60 (36)
Recurrent/chronic cough	44 (26)
Unexplained wheeze	17 (10)
Lobar collapse	15 (9)
Bronchiectasis	10 (6)
Pulmonary abscess	2 (1)
Bronchopulmonary dysplasia	1 (<1)
Ventilator dependence in the neonate	1 (<1)
Upper respiratory tract problems	
Chronic rhinorrhoea/stuffiness/obstruction	7 (4)
Sinusitis	3 (2)
Other reasons	
Asymptomatic siblings	5 (3)
Obstructive apnoea	1 (<1)
Near-miss cot death	1 (<1)

with normal ultrastructure (seven cases), or apparent absence of ciliated cells (three cases) (table 2). In those with a reduced frequency the cilia appeared dyskinetic with reduced amplitude and abnormal beat patterns. Their clinical features are summarised in table 3. All 18 children had chronic lower respiratory problems and 13 also had upper respiratory symptoms. Nine of 167 children underwent a second nasal ciliary examination after a period of treatment. In three of these ciliated cells were found to be persistently absent from the brushings, in the one case who had a bronchoscopy ciliated cells were also absent from a bronchial mucosal biopsy specimen. In the remaining six children the ciliary beat frequency was normal on the second examination. Four of the children with a low frequency or absence of ciliated cells had situs inversus (one with normal ultrastructure and three with abnormal ultrastructure) and two others had siblings with Kartagener's syndrome. Fourteen were reported by their parents

or referring paediatrician to have had either upper or lower respiratory tract problems in the first week of life. All of the children with ultrastructural abnormalities or absence of ciliated cells were noted to be symptomatic in the first week of life. This may be compared with the children with normal ciliary function where recorded symptoms occurred in only 34 out of 132 (26%) cases during the first week of life. A χ^2 analysis using Yates's correction for small numbers ($\chi^2=22.6$, $n=143$, $p<0.001$) showed this difference was highly significant.

The ultrastructural defects seen on electron microscopy in the eight cases are shown in table 4. All had either absence of inner, outer, or both inner and outer dynein arms. In addition, most also had occasional abnormalities of microtubular arrangement—usually disarrangement of the outer doublets (taking the form of transposition defects) and extra tubules. The following case report is typical of the 18 cases with abnormal ciliary function.

Table 2 *Pattern of ciliary function and ultrastructure in all 167 children investigated*

	No (sex)	Median age (years)	No with symptoms in first week of life	No with situs inversus	No with family history of Kartagener's syndrome
Cilia absent	3 (3 girls)	8.4	3	0	0
Cilia present Ciliary beat frequency <10 Hz Abnormal ultrastructural appearance on electron microscopy	8 (4 girls, 4 boys)	5.2	8	3	2
Cilia present Ciliary beat frequency <10 Hz Normal ultrastructural appearance on electron microscopy	7 (5 girls, 2 boys)	6.3	3	1	0
Cilia present Ciliary beat frequency >10 Hz	149 (67 girls, 82 boys)	4.1	34/132*	7	0
Total	167 (79 girls, 88 boys)	4.1	48/150*	11	2

*Presence of symptoms in first week of life not known or recorded in 17 cases.

Table 3 *Clinical features of 18 children with ciliary abnormalities*

Clinical features	Cilia absent (n=3)	Cilia present, ciliary beat frequency <10 Hz abnormal ultrastructural appearance on electron microscopy (n=8)	Cilia present, ciliary beat frequency <10Hz normal ultrastructural appearance on electron microscopy (n=7)
Chronic cough/chest infections	3	8	7
Chronic rhinorrhoea/stiffness/obstruction	2	6	5
Bronchiectasis/persistent lobar collapse	2	3	1
Situs inversus	0	3	1
Family history of Kartagener's syndrome	0	2	0
Sinusitis	1	1	0
Hearing defect	0	2	0

Table 4 Predominant ultrastructural defect in the eight cases with abnormal ultrastructure

Case no	Number and type of dynein arm abnormalities (% cilia counted)	Number and type of microtubular arrangement abnormalities (% cilia counted)
1	37 (86) absent inner 2 (5) both absent	31 (24) outer doublets disarranged 4 (3) outer doublets extra tubules
2	5 (19) absent inner	9 (20) outer doublets disarranged 2 (4) outer doublets extra tubules 2 (4) outer doublets single tubules
3	229 (91) absent outer 11 (4) both absent	24 (4) outer doublets extra tubules 14 (2) outer doublets disarranged
4	66 (75) absent outer	4 (2) outer doublets extra tubules 4 (2) compound cilia
5	11 (52) absent inner	15 (36) outer doublets disarranged 3 (7) central pair missing 2 (5) compound cilia
6	100 (88) both absent 12 (11) absent outer	7 (3) outer doublets extra tubules 7 (3) outer doublets disarranged
7	14 (78) both absent	1 (2) outer doublets disarranged
8	12 (86) both absent 2 (14) absent outer	2 (4) outer doublets extra tubules 1 (2) outer doublets disarranged

Case report

A 6 year old boy (case 4) with a history of chronic productive cough and nasal discharge was referred for investigation. He had been born at full term after a normal delivery and a normal pregnancy and had weighed 3800 g. Nasal stuffiness and discharge were noted from the first day of life and had required treatment with an antibiotic during the first week. From 15 months of age he had required frequent courses of oral antibiotics for chest infections and he failed to thrive. His parents first noted hearing problems when they found that they had to shout in order to draw his attention. An older brother had died at the age of 10 years after cardiac surgery for complex congenital heart disease and situs inversus. He was thought to have had Kartagener's syndrome, but had not undergone ciliary function testing. A younger sister was asymptomatic.

Examination showed a thin boy without finger clubbing. There was appreciable chest deformity (with pectus carinatum and bilateral Harrison's sulci), inspiratory crackles at the left base, purulent nasal discharge, and bilateral serous otitis media. A chest radiograph showed cardiac and abdominal situs solitus and increased shadowing in the left lower lobe. Forced expiratory volume in one second and forced vital capacity were reduced, this suggested a mixed obstructive and restrictive ventilatory defect. An ^{81}Kr ventilation scan indicated reduced ventilation in the anterior, lateral, and posterior basal segments of the left lower lobe and

the medial segment of the right upper lobe. Sweat electrolyte secretion was normal. *Haemophilus influenzae* and *Streptococcus pneumoniae* were cultured from a sputum sample.

Ciliary function was examined in an epithelial brushing of the inferior nasal turbinate. Cilia seemed dyskinetic, moving stiffly and asynchronously with reduced amplitude and had a ciliary beat frequency of less than 10 Hz. Electron microscopy (fig 2) showed outer dynein arms to be absent from

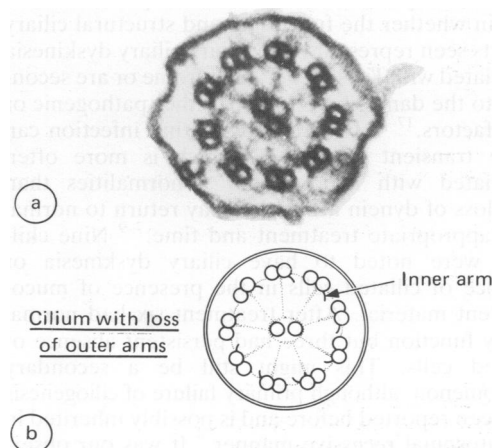


Fig 2 (a) Electron micrograph (magnification $\times 100\ 000$) and (b) schematic drawing (courtesy of A Dewar) of transverse section of a cilium from case report showing missing outer dynein arms.

75% of the cilia counted, there were occasional extra tubules adjacent to the outer doublets (2%) and compound cilia (2%). After the diagnosis of primary ciliary dyskinesia he was treated with a course of oral cefaclor for one month and started regular physiotherapy. There was some improvement in his condition notably a reduction of cough and sputum.

Discussion

Including the three cases where no ciliated cells could be found we estimated the prevalence of abnormal ciliary function to be 18 out of 167 cases (11%). In the 149 children where the ciliary beat frequency was greater than 10 Hz the cilia invariably appeared to beat in a normal coordinated pattern.

In Kartagener's syndrome it has been shown that, while the occasional patient may be found with normal ciliary function and ultrastructure, there is a clear relation between the level of reduction in ciliary beat frequency and the number of ultrastructural abnormalities present.¹⁶ Most cases have a frequency below 10 Hz with more than 50% of the dynein arms missing. Tests of ciliary function in adults often include measurement of nasal mucociliary clearance by the saccharin test in which a small particle of saccharin is placed behind the anterior border of the inferior turbinate and the time taken to perceive a sweet taste recorded. This test, however, requires considerable cooperation from the subject and, like others, we have found that the test is not suitable for children under the age of 10 years.³

In a survey of this nature it is not possible to be certain whether the functional and structural ciliary defects seen represent the primary ciliary dyskinesia associated with Kartagener's syndrome or are secondary to the damaging effects of either pathogenic or host factors.¹⁷⁻¹⁹ It is recognised that infection can cause transient dyskinesia, which is more often associated with microtubular abnormalities than with loss of dynein arms; this may return to normal with appropriate treatment and time.⁷⁻⁹ Nine children were noted to have ciliary dyskinesia or absence of ciliated cells in the presence of mucopurulent material. After treatment six had normal ciliary function but three had persistent absence of ciliated cells. This might still be a secondary phenomenon, although primary failure of ciliogenesis has been reported before and is possibly inherited in an autosomal recessive manner.⁶ It was our observation, however, that many of the children with normal ciliary function had mucopurulent nasal discharges. It is therefore probable that if ciliary function and structure are altered by infective agents

then not all pathogens have this effect. Alternatively, there may be mechanisms operating to protect cilia in those individuals with infection and normal ciliary function that are absent in those with ciliary dyskinesia. The anomalies of microtubular arrangement seen in those with missing dynein arms were infrequent and probably non-specific. Such appearances have occasionally been found in the cilia of normal individuals.^{16 20} The seven children with abnormal ciliary function but normal ultrastructure depart from the usual pattern of ciliary dyskinesia. This finding has been documented in the past and may represent a metabolic abnormality within the cilia with no morphological counterpart.^{3 4}

Fourteen of the 18 children with abnormal ciliary function, and all the children with abnormal ultrastructure or absence of ciliated cells, had symptoms starting in the perinatal period (table 2). This finding would suggest that any child with chronic lower respiratory disease starting in the perinatal period should be investigated for ciliary dyskinesia. While most of the children with ciliary abnormalities were noted to have upper respiratory problems as well this was not inevitable. It is important to make the diagnosis not only because of its implications regarding later male infertility, but also because more invasive investigations into other possible causes for the respiratory problem may be avoided. In the United Kingdom there are currently only one or two centres with facilities for investigating ciliary function and ultrastructure. This study would suggest that ciliary dyskinesia is not that uncommon in children with unexplained chronic respiratory disease and that wider facilities should be available for investigating suspected cases. Although there is no specific treatment for the condition, supportive management with regular physiotherapy and use of antibiotics may prevent or delay the onset of bronchiectasis.

This work was supported by the National Fund for Research into Crippling Diseases (Action Research for the Crippled Child). RMB is supported by a grant from the Cystic Fibrosis Research Trust.

References

- 1 Afzelius BA. A human syndrome caused by immotile cilia. *Science* 1976;193:317-9.
- 2 Rott H-D. Genetics of Kartagener's syndrome. *Eur J Respir Dis* 1983;64(suppl 127):1-4.
- 3 Greenstone M, Cole PJ. Ciliary function in health and disease. *Br J Dis Chest* 1985;79:9-26.
- 4 Greenstone MA, Dewar A, Cole PJ. Ciliary dyskinesia with normal ultrastructure. *Thorax* 1983;38:875-6.
- 5 Fonzi L, Lungarella G, Palatresi R. Lack of kinocilia in the nasal mucosa in the immotile cilia syndrome. *Eur J Respir Dis* 1982;63:558-63.
- 6 Gotz M, Stockinger L. Aplasia of respiratory tract cilia. *Lancet* 1983;ii:1283.

- ⁷ Wilson R, Sykes DA, Currie D, Cole PJ. Beat frequency of cilia from sites of purulent infections. *Thorax* 1986;**41**:453–8.
- ⁸ Rutland J, Cox T, Dewar A, Cole P, Warner JO. Transitory ultrastructural abnormalities of cilia. *Br J Dis Chest* 1982;**76**: 185–8.
- ⁹ Carson JL, Collier AM, Hu S-CS. Acquired ciliary defects in nasal epithelium of children with acute viral upper respiratory infections. *N Engl J Med* 1985;**312**:463–8.
- ¹⁰ Wilson R, Alton E, Rutman A, *et al*. Upper respiratory tract viral infection and mucociliary clearance. *Eur J Respir Dis* 1987;**70**:272–9.
- ¹¹ Corbeel L, Cornillie F, Lauweryns J, Boel M, van den Bergh G. Ultrastructural abnormalities of bronchial cilia in children with recurrent airway infections and bronchiectasis. *Arch Dis Child* 1981;**56**:929–33.
- ¹² Whitclaw A, Evans A, Corrin B. Immotile cilia syndrome: a new cause of neonatal respiratory distress. *Arch Dis Child* 1981;**56**:432–5.
- ¹³ Rutland J, Cole PJ. Non-invasive sampling of nasal cilia for measurement of beat frequency and study of ultrastructure. *Lancet* 1982;*ii*:564–5.
- ¹⁴ Greenstone M, Logan-Sinclair R, Cole PJ. An automated method of recording ciliary beat frequency. *International Research Communications Medical Science* 1984;**12**:715–6.
- ¹⁵ Rutland J, Dewar A, Cox T, Cole P. Nasal brushing for the study of ciliary ultrastructure. *J Clin Path* 1982;**35**:357–9.
- ¹⁶ Rutland J, Cox T, Dewar A, Cole P. Screening for ciliary dyskinesia—a spectrum of defects of motility and structure. *Eur J Respir Dis* 1983;**64**(suppl 127):71–7.
- ¹⁷ Wilson R, Roberts D, Cole PJ. Effect of bacterial products on human ciliary function in vitro. *Thorax* 1985;**40**:125–31.
- ¹⁸ Smallman LA, Hill SL, Stockley RA. Reduction of ciliary beat frequency in vitro by sputum from patients with bronchiectasis: a serum proteinase effect. *Thorax* 1984;**39**:663–7.
- ¹⁹ Sykes DA, Wilson R, Greenstone M, Currie DC, Steinfors C, Cole PJ. Deleterious effects of purulent sputum sol on human ciliary function in vitro: at least two factors identified. *Thorax* 1987;**42**:256–61.
- ²⁰ Rossman CM, Lee RMKE, Forrest JB, Newhouse MT. Nasal ciliary ultrastructure and function in patients with primary ciliary dyskinesia compared with that in normal subjects and in subjects with various respiratory diseases. *Am Rev Respir Dis* 1984;**129**:161–7.

Correspondence to Dr RM Buchdahl, Paediatric Department, Guy's Hospital, London SE1 9RT.

Accepted 9 October 1987