

References

- White RHR. Management of urinary tract infection. *Arch Dis Child* 1987;**62**:421-7.
- Haycock GB. Investigation of urinary tract infection. *Arch Dis Child* 1986;**61**:1155-8.
- McAlister WH, Cacciarelli A, Shackelford GD. Complications associated with cystography in children. *Radiology* 1974;**111**:167-72.

TEJ K MATTOO
Maternity and Children's Hospital,
PO Box 7855, Riyadh 11117,
Saudi Arabia

Management of urinary tract infection

Sir,

In his Personal Practice paper,¹ Professor R H R White states that in the investigation of urinary tract infections by ultrasonography 'it is prudent to combine this procedure with a plain abdominal radiograph to exclude radio-opaque calculi and facilitate review of the lumbosacral spine'.

His yield of opaque calculi may be increased if he requests a plain abdominal radiograph after a drink—a technique most x-ray departments already use for improving the results of an intravenous urogram.

Reference

- White RHR. Management of urinary tract infection. *Arch Dis Child* 1987;**62**:421-7.

S E W SMITH
Department of Radiology,
St. James's University Hospital,
Leeds
LS9 7TF

The physically handicapped school leaver

Sir,

M Ann Chamberlain contributes a generous annotation¹ based on our pamphlet 'The health and social needs of physically handicapped young adults—are they being met by the statutory services?'² We must, however, correct one or two inaccuracies.

Chamberlain refers to the report as 'The Spastics' Society Report'. It was of course written by us and is not a report from the Spastics' Society, and certainly does not represent either their policies or necessarily their views. The views are our own.

In the penultimate paragraph she quotes the report as suggesting that we were proposing a sub specialist grade to treat adolescents. We were, in fact, careful not to do this. We talked about the setting up of a district based handicapped adult team and would agree with her view that an adult specialist needs to be appointed to take on this task.

References

- Chamberlain MA. The physically handicapped school leaver. *Arch Dis Child* 1987;**62**:3-5.

- Bax M, Coombes K, Goldson E, Smith D, Whitmore K. The health and social needs of physically handicapped young adults: are they being met by the statutory services? *Dev Med Child Neurol* [Suppl] 1985;**27**:1-20.

M BAX
Community Paediatric Research Unit,
Westminster Children's Hospital,
London SW1P 2NS

Varioliform gastritis and campylobacter-like organisms

Sir,

We read with interest the report of a paediatric case of varioliform gastritis by Caporali *et al.*¹ supporting the idea that this endoscopic picture has an allergic aetiology. We have recently reviewed our upper digestive endoscopy findings in children retrospectively looking for histologic evidence of campylobacter-like organisms. Among children with histologic evidence of such infection of gastric mucosa we found a 9 year old girl who was admitted with anorexia, epigastric pain, and vomiting. Endoscopy showed typical scattered umbilicated papular lesions called varioliform gastritis in the antrum and the body of the stomach. Histological examination showed poly- and mononuclear infiltration in gastric specimens (fig 1) associated with the presence of bacteria under the mucus layer (fig 2). No evidence of in vivo or in vitro food allergy was found. Follow up of this patient was not possible because she moved to another country.

Recently campylobacter-like organisms were shown to be associated with gastritis, and gastric and duodenal ulcers both in adults and in children.² Even though a specific endoscopic picture has not been described, the occurrence of antral nodularity and histological gastritis has been found in children with this disease.²⁻³ The

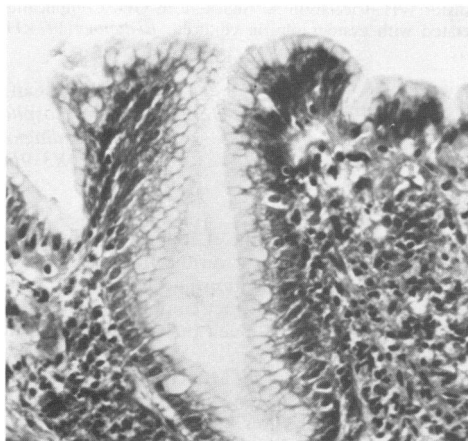


Fig 1 Diffuse interstitial inflammation of antral mucosa with irregular cell profiles. Giemsa.