

Outbreaks of hand, foot, and mouth disease by enterovirus 71

High incidence of complication disorders of central nervous system

YOSHIRO ISHIMARU, SHOZO NAKANO, KUNIO YAMAOKA, AND SHUNSAI TAKAMI

Ishimaru Paediatric Clinic, Matsuyama, Ehime, Japan

SUMMARY In Japan we have had two outbreaks of hand, foot, and mouth disease associated with disorders of the central nervous system, one in 1973 and the other in 1978. The isolated virus in both outbreaks was enterovirus 71. Central nervous system disorders were present in 24% of patients in 1973 and in 8% of patients in 1978. These disorders were localised encephalitis with cerebellar signs as the main feature, aseptic meningitis, and polio-like paresis. The enterovirus 71 isolated in Japan had strong dermatotropic as well as neurotropic tendencies. However in cross-neutralisation tests, no difference in antigenicity from the prototype, BrCr strain, was recognised.

In Japan we have had four outbreaks of hand, foot, and mouth disease (HFMD)—in 1970, 1973, 1975, and 1978. Hitherto, this disease caused by coxsackievirus A16 had been considered to be benign.¹⁻² However, in the 1973 and 1978 outbreaks, many patients had central nervous system (CNS) disorders in addition to skin manifestations.³⁻⁶ Some of these patients died and others had serious sequelae. In such cases, enterovirus 71 was isolated as the pathogenic agent. This suggested that, despite identical skin manifestations, HFMD could be caused by two different pathogenic agents, coxsackievirus A16 and enterovirus 71, associated with different syndromes. Reports from the USA and Australia have shown that enterovirus 71 is strong in neurotropism but very weak in dermatotropism.⁷⁻⁹ However, enterovirus 71 isolated in Japan seemed to have a dermatotropic character as well as a neurotropic one.

Materials and methods

The subjects studied were children visiting Ishimaru Paediatric Clinic, Matsuyama, Japan as outpatients. Their ages ranged from 0 to 16 years. The sera of their mothers were tested, too.

Examinations for the viruses were carried out in throat swabs, stools, vesicle fluid, and cerebrospinal fluid collected from each patient with HFMD at his first visit to the clinic. Serum was collected at the

patient's first visit for the acute phase, and at another visit made at least 15 days later for the convalescent phase. The isolation of virus was performed using primary rhesus monkey kidney cells in 1973, and the established cell lines of African green monkey kidney in 1978. Isolated viruses were identified by the neutralisation test first, with 20 units of Schmidt pool serum. If the virus could not be identified by this procedure it was then tested with 100 units of antiserum against enterovirus 71 prototype strain (BrCr).

The titration of neutralising antibody against enterovirus 71 and coxsackievirus A16 in the paired sera of the patients, in the sera of the subjects, and in the cross-neutralisation test of the viruses was performed by the 80% plaque reduction technique with carboxymethylcellulose overlay medium using green monkey kidney cells. In a very few cases in 1973 antibody titres to enterovirus 71 of the patients were performed by complement-fixation test. The titres of neutralising antibody to coxsackievirus A9 and coxsackievirus B5 were determined by micro-plate technique using primary rhesus monkey kidney cells, and expressed as 50% neutralising titres.

Results

Epidemiological background. The percentage of the population who had antibody to enterovirus 71 and coxsackievirus A16 is shown in Fig. 1. In 1972 and

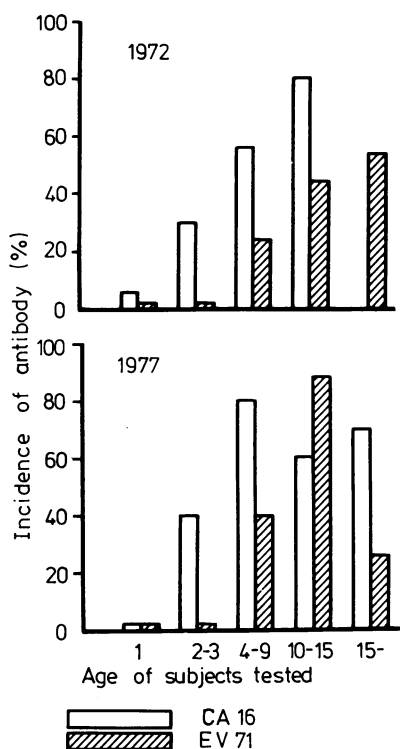


Fig. 1 Evidence of neutralising antibody to enterovirus 71 and coxsackievirus A16 in the population tested.

1977, no one under age 4 years had the antibody. 20–40% of children between 4 and 9 years and 40–70% of those between 10 and 15 years possessed the antibody. Antibody to coxsackievirus A16 (G-10) could not be found in 35–80% of the subjects older than age 2 years.

Outbreak of HFMD associated with CNS disorder.

The outbreak of HFMD in 1973 started with the first case on 21 July. Subsequently there were 335 more: 36 in July, 156 in August, 114 in September, 27 in October, and 2 in November. In 1977, 1 case was observed in May, and 2 in September. In 1978, there were 2 cases in January. The outbreak started with 121 cases in May, 426 in June, and 173 in July. In August the epidemic receded rapidly with only 9 cases that month, and 3 in September. Altogether there were 692 cases in that outbreak.

The age distribution of patients with HFMD in the outbreaks in 1973 and 1978 is shown in Fig. 2. In 1973 the highest incidence was in 1-year-old children, as had been the case in earlier outbreaks of HFMD by coxsackievirus A16. The next highest incidence

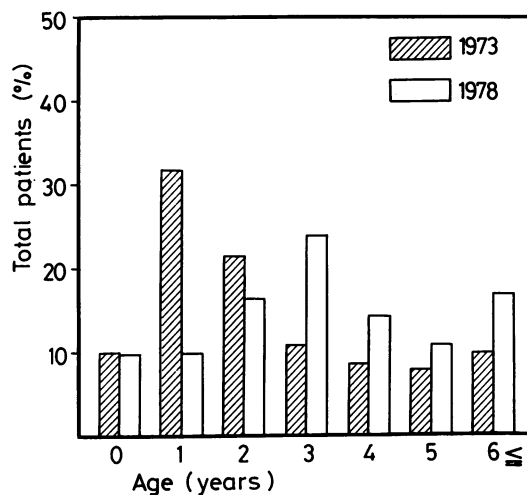


Fig. 2 Age distribution of patients with hand, foot, and mouth disease in 1973 and 1978.

was in 2-year-old children; and the 0–2-year-old age group constituted 64% of all patients. In 1978 the highest incidence was in 3-year-old children, followed by 2-year-old and then by 4-year-old children. The youngest infant affected was 42 days old and his mother was affected too. There were 189 boys and 148 girls in the 1973 outbreak, making the male to female ratio 1.3:1. In 1978 there were 343 boys and 349 girls, making the male to female ratio approximately unity.

Clinical symptoms in HFMD cases with CNS disorder.

The skin eruption in these outbreaks was similar to that in outbreaks reported by others, both in its appearance and distribution. It was manifested as papules and vesicles accompanied by flare on the hands and feet, and aphthae on tongue and oral mucosa. In infants of 2 years or less however, fine macular papules and diffuse erythema and rash were observed on the thighs, buttocks, upper limbs, and the trunks.

In addition to the skin manifestations characteristic of HFMD, some of the patients had the following symptoms: (1) fever for more than 3 days, (2) headache or vomiting or both, (3) irritability, somnolence, tremor, ataxia, and myoclonus, and (4) flaccid monoparesis in the lower extremity. In 81 of 86 patients who had these symptoms, cerebrospinal fluid showed pleocytosis suggesting CNS disorder. 81 (24%) of 335 cases in 1973, and 54 (8%) of 692 cases in 1978 had symptoms or laboratory data that suggested CNS disorders. CNS complications were present in infants of all ages. The highest

incidence was in 1-year-old infants, 38.5% of whom had CNS disorders. In most of them, the onset of CNS disorders was noticed between day 2 and day 4 after the onset of skin eruption. The clinical features relating to CNS disorders in these patients, based on observations made in 1973, are shown in Table 1. Nausea and vomiting were present in 43% of these patients. However, these symptoms constituted only 33% of the patients whose main clinical features were ataxia, and tremor or myoclonus (or both). Exaggerated deep tendon reflexes were seen in 77% of them. However, this sign fluctuated according to the time of examination. Intention tremor was seen in 59% and myoclonus in 26%. When we studied sleep disturbances—such as nightmares or crying—it appeared that these children had been awakened by myoclonus of the extremities or of the whole body. Ataxia was seen in 47%. These children tottered or walked beside a wall, walked with wide-based legs, or with short steps, or with staggering on one side, and sometimes they could not walk. The deep tendon reflexes of such children were not decreased. Tremor, myoclonus, and ataxia generally disappeared between 2 and 4 days after the onset. However, in a few children ataxia persisted for between 10 and 20 days.

There was no serious disturbance of consciousness. There were complaints of somnolence or lethargy in 6 patients, and visual hallucination in one. There were 2 cases of flaccid monoparesis in the lower extremities; both patients recovered in 40 days.

Thus the pattern of neurological manifestations could be categorised as follows:

Type 1. An illness with no sign of cerebral dysfunction or meningeal irritation, associated with fever persisting for more than 3 days and pleocytosis in cerebrospinal fluid.

Type 2. Meningitis accompanied by signs of meningeal irritation.

Table 1 Signs and symptoms in 81 patients with hand, foot, and mouth disease who also had disorders of the central nervous system

Signs and symptoms	No of cases
Headache	12
Vomiting	35
Kernig's sign	29
Nuchal rigidity	14
Nightmares	17
Irritability	7
Knee jerk	
hyperreflexia (fluctuated)	63
hyporeflexia	3
Intention tremor	48
Truncal ataxia	38
Myoclonus	21
Nystagmus	2
Flaccid monoparesis	2

Type 3. Localised encephalitis affecting mainly the cerebellum, manifesting itself as ataxia, myoclonus, and tremor.

Type 4. Flaccid monoparesis, suggesting injury to anterior horn cells or to peripheral nerves.

The incidence of each type is summarised in Table 2. In the outbreak in 1973, the principal manifestation of neurological disorder was type 3, whereas in 1978 it was type 1.

The findings of cerebrospinal fluid test are shown in Table 3. These results are similar to those for aseptic meningitis by other strains of enterovirus. There was no difference in the findings between patterns of illness.

Electroencephalograms (EEGs) were obtained from 24 patients with type 3 during the acute phase of illness. There were 9 cases of dysrhythmia, and 10 of sporadic synchronous high-voltage slow waves. However, no finding indicated serious cerebral dysfunction. The overall assessment of EEG findings was normal in 8 cases, borderline in 6, and showed

Table 2 Incidence of each type of central nervous system disorder in two outbreaks of hand, foot, and mouth disease

Type*	Incidence	
	In 1973	In 1978
1	5	24
2	15	6
3	59	24
4	2	0

* See text.

Table 3 Findings of cerebrospinal fluid according to the pattern of illness*

	Number of cases		
	Type 1	Type 2	Type 3
Cell count ($\times 10^6/l$)			
10-30	0	4	4
31-170	4	5	29
171-300	1	4	20
301-	0	2	6
Polymorphs (% of cell count)			
-30	3	12	39
31-70	2	3	19
71-90	0	0	4
Protein content (mg/100 ml)			
-30	2	5	8
31-50	2	4	24
51-	0	5	27
Sugar content (mg/100 ml)			
-40	0	0	0
41-70	3	9	27
71-	2	5	32

Conversion: traditional units to SI—protein: 1 mg/100 ml \approx 0.01 g/l, glucose: 1 mg/100 ml \approx 0.0555 mmol/l.

*Clinical features presented by each type of pattern of illness are described in text.

Table 4 Isolation of enterovirus 71 and other viruses from patients with hand, foot, and mouth disease

Specimen	1973			1978		
	No examined	Enterovirus 71 (%)	Other viruses	No examined	Enterovirus 71 (%)	Other viruses
Throat swab	13	3 (23)	1*	57	20 (35)	2†
Vesicle fluid	20	11 (55)		22	6 (27)	
Faeces	73	18 (25)	2*	32	11 (34)	1‡
Cerebrospinal fluid	86	1 (1)	1*	22	1 (5)	

*Coxsackievirus B5, †poliovirus 2 and parainfluenza virus 3, ‡adenovirus 5.

cerebral dysfunction in 10 cases. EEGs were obtained from 42 patients with the same type at 3 months and then 12 months later. All were normal except one.

Developmental tests were performed 3 months and 12 months after the onset of illness. The results were all in the normal range. One year later, there were no symptoms of minimal brain dysfunction—such as lack of concentration, abnormal behaviour, or clumsiness.

ECGs were taken from 42 patients in the acute phase. In one case, there was sinus arrhythmia, but one week later it was normal. There were 2 cases of transient albuminuria.

Virological tests. The results of virus isolation are summarised in Table 4. In 1973, 37 strains were successfully isolated. In a few cases, coxsackievirus B5 was isolated from throat swabs, but not from vesicle fluid. Virus was isolated from cerebrospinal fluid in only 2 patients. 33 strains which could not be identified as coxsackievirus B5 with Schmidt pool serum were all neutralised by 20 units of enterovirus 71 (BrCr) antiserum.

Results of virus isolation in the outbreak of 1978 (Table 4) were similar to those of 1973, the only difference being that 3 strains of para influenza were isolated as nonenterovirus 71. Furthermore, 10

Table 5 Neutralisation test with various epidemic strains of enterovirus 71 and 3 standard antisera against enterovirus 71 and coxsackievirus A16

Virus strain code no	Specimen for virus isolation	Reciprocal for antibody titre		
		Anti-EV 71 (BrCr) (2560)†	Anti-73-2118* (1280)†	Anti-CA16 (G-10) (3200)†
73-2038*	Vesicle fluid	1600	400	<10
73-2039	Vesicle fluid	3200	800	<10
73-2049	Vesicle fluid	1600	800	<10
73-2068	Vesicle fluid	3200	1600	<10
73-2161	Vesicle fluid	1600	800	<10
73-2089	Throat swab	800	400	<10
73-2381	Throat swab	1600	400	<10
73-2155	Faeces	3200	800	<10
73-2160	Faeces	1600	800	<10
73-2205	Faeces	3200	200	<10

*Ev 71 strains isolated in 1973.

†The figure in parentheses is the homologous titre of the indicated antiserum.

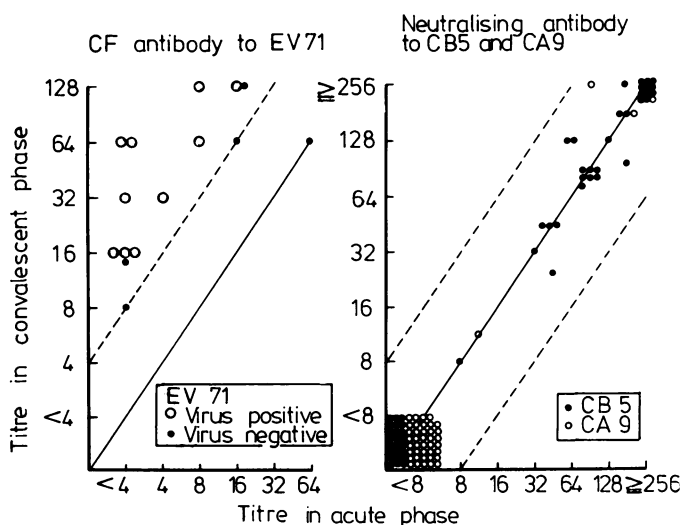


Fig. 3 Changes in antibody titre to enterovirus 71, coxsackievirus B5, coxsackievirus A9 in paired sera of patients with hand, foot, and mouth disease in whom central nervous system disorders were present.

strains isolated were readily neutralised even by 800- to 3200-fold dilution of anti-BrCr serum, but were not neutralised by anti-G-10 serum (Table 5). Similar results were obtained with strains isolated in 1978.

In 1973 there were epidemic outbreaks of aseptic meningitis and febrile illness caused by coxsackievirus B5, coxsackievirus A9, and echo 6 about the same time as the outbreak of HFMD in the Matsuyama area. Therefore, it is possible that the CNS disorder accompanying HFMD was caused by these other viruses. To exclude this possibility, we tested for changes in the titre of neutralising antibody to coxsackieviruses B6, A9, and A16 in the patients. The results are shown in Fig. 3. Only the antibody to enterovirus 71 showed a significant rise in titre.

From these results, we concluded that the pathogenic agent of the CNS disorders that accompanied HFMD in the outbreaks in 1973 and 1978 was enterovirus 71.

Discussion

We have experienced four outbreaks of HFMD. The pathogenic agent of the outbreaks in 1973 and 1978 was enterovirus 71, whereas that in the others was coxsackievirus A16. The skin eruption caused by enterovirus 71 was identical with that caused by coxsackievirus A16. In older patients the pattern was fairly typical; in patients aged less than 1 year fine macular papules and erythema, as described by Kennett *et al.*,⁹ were often found on the thighs, buttocks, upper limbs, or trunk.

CNS complications were observed in 24% of patients in 1973 and in 8% of patients in 1978. In 96% of these the CNS disorder appeared between days 2 and 4 after the onset of HFMD. The male to female ratio was 1.3:1 in 1973, similar to that found with other strains of enterovirus. However in 1978 it was about unity.

The neurological manifestations were variable, comprising meningitis, localised encephalitis, and flaccid monoparesis. In the cases of localised encephalitis, there were no fits or disturbances of consciousness to suggest serious cerebral dysfunction. The only significant findings in the EEGs were dysrhythmia and sporadic synchronous high-voltage slow waves. These findings suggest that the illness should be regarded as slight cerebral dysfunction rather than as encephalitis. There were many cases with truncal ataxia which suggested cerebellar vermis dysfunction and many with intention tremor, inability to walk straight, and nystagmus which suggested cerebellar hemispheric dysfunction. The lesion causing myoclonus is thought to be in thalamic or subthalamic reticular structures. Therefore, we concluded that the encephalitis

caused by enterovirus 71 was localised mainly in the cerebellum and partly in the brainstem and the basal ganglia. This accords with the findings obtained at necropsy in crab-eating monkeys inoculated with enterovirus 71 which were described by Hagiwara *et al.*¹¹ Previous reports of illness caused by enterovirus 71 include encephalitis with meningitis,⁷⁻⁸ and meningitis only.⁹⁻¹⁰ However, further and more careful observation is necessary, because the main site affected appears to vary according to the infective strain. Furthermore, there were 2 cases with flaccid monoparesis affecting the lower extremities. In these cases, the knee jerk was diminished and the disturbance in the anterior horn cells or peripheral nerves was suspected.

Attempts at virus isolation were made from vesicle fluid, stools, throat swabs, and cerebrospinal fluid by using cells from green monkey kidneys and primary rhesus monkey kidneys. In 1973, virus was isolated from 34% of patients, but it could only be isolated from cerebrospinal fluid in 2 patients. The isolated viruses were all identified as enterovirus 71 except 5 strains which were identified as coxsackievirus B5. Also 10 strains randomly selected were neutralised by antiserum to enterovirus 71 (BrCr). None was neutralised by antiserum to coxsackievirus A16.¹² In 1978, 48 strains were isolated from 130 subjects, and 45 were identified as enterovirus 71 by 20 units of antiserum to enterovirus 71 (BrCr). In neither outbreak was any virus, other than enterovirus 71, isolated from vesicle contents. Both in 1973 and 1978, a significant rise in neutralising titres against enterovirus 71 only was observed both in patients from whom enterovirus 71 was isolated and in those who were negative in the virus test. From these findings, it was concluded that the pathogenic agent of HFMD in both 1973 and 1978 was enterovirus 71. Despite the fact that no antigenic difference from the prototype BrCr was recognisable (Table 5), the enterovirus that we isolated was a strain with an extremely strong dermatotropic character rather than a neurotropic one. It seemed that this dermatotropic tendency was more evident in the 1978 strain than in the 1973 strain. It was very interesting that, despite the similarity in the antigenic character, enterovirus 71 was so different in organotropic character according to the isolated strains. Attention should be directed to the organotropic character of this virus in future.

We thank Dr G Toda, First Department of Internal Medicine, Tokyo University School of Medicine, for reviewing the manuscript.

Presented in part at the Fourteenth International Congress of Paediatrics, Buenos Aires, 1974.

References

- ¹ Robinson C R, Frances W D, Rhodes A J. Report of outbreak of febrile illness with pharyngeal lesions and exanthema: Toronto summer 1957 isolation of group A Coxsackie virus. *Can Med Assoc J* 1958; **79**: 615-21.
- ² Alsop J, Flewett T H, Foster J R. Hand, foot, and mouth disease in Birmingham in 1957. *Br Med J* 1960; **ii**: 1708-11.
- ³ Ishimaru Y, Isshiki M, Yamaoka K. Hand-foot-mouth disease complicated by aseptic meningitis with cerebellar syndrome (in Japanese). *Igaku No Ayumi* 1974; **89**: 108-9.
- ⁴ Tagaya I, Tachibana K. Epidemic of hand, foot, and mouth disease in Japan 1972-1973: difference in epidemiologic and virologic features from previous one. *Jpn J Med Sci Biol* 1975; **28**: 231-4.
- ⁵ Ishimaru Y, Nakano H, Yamada K. Recent infectious disease associated with enterovirus (in Japanese). *J Pediatr Practice* 1978; **41**: 999-1005.
- ⁶ Hagiwara A, Tagaya I, Yoneyama T. Epidemic of hand, foot, and mouth disease with enterovirus 71 infection. *Intervirology* 1978; **9**: 60-3.
- ⁷ Schmidt N J, Lennette E H, Ho H H. An apparently new enterovirus isolated from patients with disease of central nervous system. *J Infect Dis* 1974; **129**: 304-9.
- ⁸ Deibel R, Gross L L, Collins D N. Isolation of a new enterovirus. *Proc Soc Exp Biol Med* 1975; **148**: 203-7.
- ⁹ Kennett M L, Birch C J, Lewis F A, Yung A P, Locarnini S A, Gust I D. Enterovirus type 71 infection in Melbourne. *Bull WHO* 1974; **51**: 609-15.
- ¹⁰ Blomberg J, Lycke E, Ahlfors K, Johnsson T, Wolontis S, von Zeipel G. Letter: New enterovirus type associated with epidemic of aseptic meningitis and/or hand, foot and mouth disease. *Lancet* 1974; **ii**: 112.
- ¹¹ Hagiwara A, Hashimoto S. Neurotrope of enterovirus 71 (in Japanese). *Clin Virol* 1978; **6**: 77-8.
- ¹² Takami S, Yamaoka K. Epidemic of hand-foot-mouth disease associated with enterovirus 71 in Ehime Prefecture (in Japanese). *Clin Virol* 1979; **7**: 104-8.

Correspondence to Dr Yoshiro Ishimaru, Ishimaru Paediatric Clinic, 6-5-2 Sanban-cho, Matsuyama, Ehime, Japan 790.

Received 15 August 1979