

Initially these observations led to the 'leaky' lysosomal membrane hypothesis (Wiesmann *et al.*, 1971). However, Hickman and Neufeld (1972) showed that I-cell fibroblasts were able to pinocytose and retain exogenous lysosomal acid hydrolases from normal sources. They proposed that in I-cell disease the plasma membrane is unable to recognise the secreted exogenous acid hydrolases due to lack, or alteration, of a recognition marker in the hydrolase molecule and therefore cannot pinocytose them for incorporation into lysosomes. Thus I-cell disease is characterised by massive urinary secretion of sialyl oligosaccharides, increased acid hydrolase activity in plasma and the media of cultured fibroblasts, and the acid hydrolases secreted by cultured fibroblasts being more electronegative than intracellular hydrolases. Recently Strecker *et al.* (1976) have shown that patients with I-cell disease have a deficit of neuraminidase. Such a deficit would account for the above features by failure to remove n-acetylneuraminic acid from the oligosaccharide residue, thereby unmasking the recognition marker of the secreted glycoprotein, and is compatible with Hickman and Neufeld's hypothesis.

Prenatal diagnosis has been undertaken successfully (Aula *et al.*, 1975). Ultimately assay of the basic mutant enzyme will become available, but at present plasma aryl sulphatase A activity is a reliable screening test.

Summary

A boy with fatal I-cell disease is reported. Defective ganglioside and glycoprotein metabolism is due to deficient neuraminidase activity.

I thank Professor O. H. Wolff and Dr A. D. Patrick for advice and encouragement, and Mrs E. Young for the enzyme assays.

References

- Aula, P., Rapola, J., Autio, S. K., Raivio, K., and Karjalainen, O. (1975). Prenatal diagnosis and fetal pathology of I-cell disease (mucopolipidosis type II). *Journal of Pediatrics*, **87**, 221-226.
- Hickman, S., and Neufeld, E. F. (1972). A hypothesis for I-cell disease: defective hydrolases that do not enter lysosomes. *Biochemical and Biophysical Research Communications*, **49**, 992-999.
- Leroy, J. G., Spranger, J. W., Feingold, M., Opitz, J. M., and Crocker, A. C. (1971). I-cell disease: a clinical picture. *Journal of Pediatrics*, **79**, 360-365.
- Strecker, G., Michalski, J. C., Montreil, J., and Farriaux, J. P. (1976). Deficit in neuraminidase associated with mucopolipidosis II (I-cell disease). *Biomedicine*, **25**, 238-240.
- Tondeur, M., Vamos-Hurwitz, E., Mockel-Pohl, S., Dereume, J. P., Cremer, N., and Loeb, H. (1971). Clinical, biochemical and ultrastructural studies in a case of chondrodystrophy presenting the I-cell phenotype in tissue culture. *Journal of Pediatrics*, **79**, 366-378.
- Wiesmann, U. N., Vassella, F., and Herschkowitz, N. (1971). I-cell disease: leakage of lysosomal enzymes into extracellular fluids. *New England Journal of Medicine*, **285**, 1090-1091.
- Wiesmann, U. N., Vassella, F., and Herschkowitz, N. N. (1974). Mucopolipidosis (I-cell disease): a clinical and biochemical study. *Acta Paediatrica Scandinavica*, **63**, 9-16.

P. J. MILLA

Department of Child Health, Institute of Child Health, 30 Guilford Street, London WC1N 1EH.

Use of the diving reflex to treat supraventricular tachycardia in an infant*

Paroxysmal supraventricular tachycardia is a medical emergency in which the most commonly used therapy is DC shock or digitalis. The diving reflex in mammals has been known since the last century (Bert, 1870) and the subject has been more recently reviewed (Andersen, 1966). Its use in the treatment of supraventricular tachycardias has been reported by several authors (Wayne and Killip, 1967; Wildenthal *et al.*, 1975; Whitman *et al.*, 1977). We report a case of its use in an infant with a method not previously reported.

Case report

A 26-day-old female infant was brought to hospital with a 2-week history of coryza. Shortly before admission she had vomited and was noted to be very pale. She was a 2-week post-term normal delivery and there had been no other problems since birth.

On examination she was markedly pale but active, and there was no cyanosis. The chest was clear and there was no hepatosplenomegaly or oedema. Heart sounds were normal and there were no added sounds, but the rate was approximately 250 beats/min. Systolic blood pressure was 60 mmHg. Peripheral pulses were good and no other abnormalities were found. After transfer to the intensive care unit, she was found to have a supraventricular tachycardia with a rate of 330 beats/min (Fig. 1). She was placed in the left lateral position, and while one ice cube was rubbed across the upper lip and bottom part of the nose, a second ice cube was rubbed across the nose from side to side. 30 to 45 seconds later, when the baby was starting to splutter, the heart rate dropped to 100 beats/min, recovering 10

*See also Correspondence, p. 520. Ed.

seconds later to a rate of 150 beats/min in sinus rhythm (Fig. 2). She was then digitalised and has remained in sinus rhythm at a normal rate.

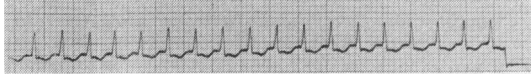

Fig. 1 ECG showing paroxysmal supraventricular tachycardia.

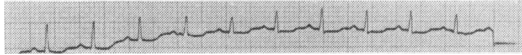


Fig. 2 ECG after application of ice cubes, in sinus rhythm.

Discussion

It is thought that cardioversion in such cases occurs because of an increase in vagal tone (Wildenthal *et al.*, 1975). A multifactorial theory for the sudden increase in vagal tone was proposed (Song *et al.*, 1969) which included the application of cold stimuli to the face as a possible trigger. There are, however, practical difficulties in inducing the diving reflex in very young patients. These could be overcome by endotracheal intubation and face immersion, or by the local application of ice cubes.

Notably, cardioversion in our case did not occur until after water from melting ice entered the vestibule of the nose. In the domestic duck, section of branches of the ophthalmic division of the trigeminal nerve abolishes the cardiac response to application of cold water to the beak (Andersen, 1963). In the human, the anterior ethmoidal nerve supplies a similar region: the mucous membrane of the frontal part of the nasal septum, the anterior part of the nasal cavity, and the skin of the ala, apex, and vestibule of the nose.

It has been suggested that the diving reflex may be

more active in small children than in adults (Gooden, 1972). If this is so, induction of the diving reflex as here described may be a simple and relatively safe way of treating supraventricular tachycardias in young children.

Summary

A simple method for treating supraventricular tachycardias is described—ice cubes are applied to the nose and upper lip. It should be particularly useful in younger children and depends on a sound physiological principle.

We are grateful to Dr J. Martin for permission to report this case.

References

- Andersen, H. T. (1966). Physiological adaptations in diving vertebrates. *Physiological Reviews*, **46**, 212–243.
- Bert, P. (1870). *Leçons sur la Physiologie Comparée de la Respiration*. Baillière, Paris.
- Gooden, B. A. (1972). Drowning and the diving reflex in man. *Medical Journal of Australia*, **2**, 583–587.
- Song, S. H., Lee, W. K., Chung, Y. A., and Hong, S. K. (1969). Mechanism of apneic bradycardia in man. *Journal of Applied Physiology*, **27**, 323–327.
- Wayne, T. F., Jr., and Killip, T., III. (1967). Simulated diving in man: comparison of facial stimuli and response to arrhythmia. *Journal of Applied Physiology*, **22**, 800–807.
- Whitman, V., Friedman, Z., Berman, W., Jr., and Maisels, M. J. (1977). Supraventricular tachycardia in newborn infants: an approach to therapy. *Journal of Pediatrics*, **91**, 304–305.
- Wildenthal, K., Leshin, S. J., Atkins, J. M., and Skelton, C. L. (1975). The diving reflex used to treat paroxysmal atrial tachycardia. *Lancet*, **1**, 12–14.

I. F. M. GRAHAME and I. M. HANN

Alder Hey Children's Hospital, Liverpool.

Correspondence to Dr I. M. Hann, Royal Manchester Children's Hospital, Manchester M27 1HA.