

lesion in the diencephalon could also possibly stimulate the thalamo-hypothalamo-hypophyseal-adrenal axis. Catecholamine secretion should therefore be investigated in these infants.

Our findings of moderate increase of (N) in the urine and an over ten-fold increase of (E) may reflect overstimulation of the sympathetic nervous system, or actual secretion from the neoplastic tissue itself. (E) and (N) were not measured in the CSF; catecholamines are said not to cross the blood brain barrier (Axelrod and Weinshilbom, 1972). Our patient had most of the symptoms attributed to stimulation of the autonomic nervous system, such as euphoria, irritability, and skin pallor; she also had a mild but constant hypertension ( $115/75 \pm 5/5$  mmHg).

In conclusion, we suggest that some of the symptoms in the diencephalic syndrome may be due to catecholamine oversecretion.

### Summary

In an infant of 15 months with the diencephalic syndrome, urinary excretion of norepinephrine was moderately raised and epinephrine greatly so. It is suggested that catecholamine secretion may be due to sympathetic stimulation at the level of the diencephalon, by a space-occupying lesion pressing on the thalamohypothalamic pathway. Some of the symptoms of the diencephalic syndrome such as euphoria, irritability, skin pallor, and hypertension may be the result of catecholamine secretion.

### References

- Addy, D. P., and Hudson, F. P. (1972). Diencephalic syndrome of infantile emaciation. *Archives of Disease in Childhood*, **47**, 338-343.
- Axelrod, J., and Weinshilbom, R. (1972). Catecholamines. *New England Journal of Medicine*, **287**, 237-243.
- Bain, H. W., Darte, J. M. M., Keith, W. S., and Kruffy, E. (1966). The diencephalic syndrome of early infancy due to silent brain tumor: with special reference to treatment. *Pediatrics*, **38**, 473-482.
- Burr, I. M., Slomin, A. E., Danish, R. K., Gadoth, N., and Butler, I. J. (1976). Diencephalic syndrome revisited. *Journal of Pediatrics*, **88**, 439-444.
- Crout, J. R. (1961). Catecholamines in urine. Cited by Seligson, D. *Standard Methods of Clinical Chemistry*, pp. 62-64. Academic Press, New York.
- Evans, C. H., Westfall, V., and Atuk, N. O. (1972). Astrocytoma mimicking features of pheochromocytoma. *New England Journal of Medicine*, **286**, 1397-1399.
- Lieberman, E. (1974). Essential hypertension in children and youth: a pediatric perspective. *Journal of Pediatrics*, **85**, 1-11.
- Russell, A. (1951). A diencephalic syndrome of emaciation in infancy and childhood. (Abst.) *Archives of Disease in Childhood*, **26**, 274.
- T. KARPATIOS, P. NICOLAIDOU, A. FRETZAGIAS, S. HAIDAS, and T. THOMAIIDIS  
*First Department of Paediatrics, Athens University, Aghia Sophia Children's Hospital, Athens 608, Greece.*

Correspondence to Dr T. Thomaidis.

## I-cell disease

I-cell disease is an inherited condition clinically resembling Hurler's disease but without excessive urinary mucopolysaccharide excretion. In contrast to Hurler's disease the clinical and radiological signs are already marked in early infancy with progressive mental retardation and death from respiratory infection in infancy or early childhood. Recent work (Strecker *et al.*, 1976) suggests that the basic defect is a deficit of neuraminidase. A further case is here reported, and the differential diagnosis and pathogenesis of the condition are discussed.

### Case report

The second child of healthy unrelated parents was born at 38 weeks' gestation by breech delivery and weighed 3.1 kg. Fetal movements had been noticeably fewer than in the previous pregnancy. At birth he was noted to have an unusual facial appearance and a narrow chest. During the neonatal period he developed mild transient jaundice and was sleepy and slow with feeds. Over the next 4 months his development was slow and he suffered several respiratory tract infections.

At age 4 months he was admitted to hospital for investigation. He had an unusual appearance (Fig.) with a high prominent forehead, flattened supra-orbital ridges, a flat nasal bridge, and anteverted nostrils. Prominent epicanthic folds and a mongoloid slant gave him a sleepy appearance. The gums were swollen and the distance between mouth and nose increased. The chest was narrow and there was a dorsolumbar kyphoscoliosis. The liver was enlarged and palpable to 3 cm, the spleen was not palpable. The hands and feet were broad and his thumbs were held enclosed by his first and second fingers.

The skin showed varying degrees of thickening particularly over the shoulders and around the wrists. Passive movements about the limb girdles were restricted. He had generalised hypotonia with persistence of primitive grasp and walking reflexes. Head control was poor, and he was only just able to raise his head in the prone position. He could smile, follow with his eyes, and vocalise freely.

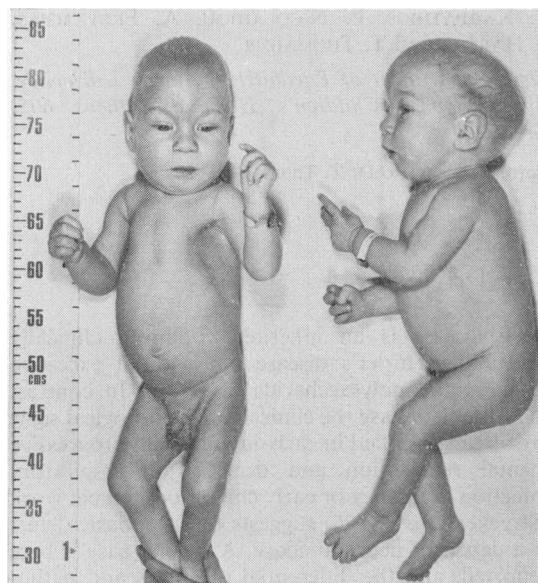


Fig. Patient aged 4 months. The facies, narrow chest, and lumbar kyphosis are clearly seen.

Slit-lamp examination of the cornea showed diffuse fine granularity of the anterior one-third of the corneal stroma. A precorneal tear film had an abnormal iridescence. The maculae were normal.

**Investigations.** Hb 11 g/dl, white cell count  $13.6 \times 10^9/l$ , normal differential count. 10% of lymphocytes in the peripheral blood showed cytoplasmic vacuoles. Serum alkaline phosphatase 100 KA U/100 ml. Screening for mucopolysacchariduria showed a slightly raised urinary glycosaminoglycan/creatinine ratio of 331 (normal 105–305). Skeletal x-rays showed a J-shaped sella turcica, anterior expansion of the ribs, a dorsolumbar kyphoscoliosis, and a bullet-shaped deformity of the metacarpals with coarseness of the trabecular pattern.

Skin fibroblast cultures showed the typical intracellular inclusions of I-cell disease. Lysosomal enzymes were assayed in white blood cells, plasma, and urine; the results are shown in the Table.

**Progress.** After discharge from hospital he remained well but made little developmental progress until age 6 months when he developed bronchopneumonia and died.

### Discussion

I-cell disease takes its name from the striking intracellular inclusions seen in cultured fibroblasts. The

Table Results of blood enzyme assays

Enzyme	White blood cells (nmol/mg per hour)	Plasma ( $\mu$ mol/ml per hour)
$\alpha$ -Galactosidase	112 (normal)	4200 ( $\times$ 40 normal)
$\beta$ -Galactosidase	45 (normal)	337 000 (normal—not detectable)
Hexosaminidase	2600 (normal)	18.4 ( $\times$ 13 normal)
$\alpha$ -Mannosidase pH 4.0	7.0 (normal)	18.4 ( $\times$ 263 normal)
$\alpha$ -Fucosidase	28 (normal)	16.3 ( $\times$ 13 normal)
Aryl sulphatase A	40 (normal)	Grossly raised (normal—not detectable)
Acid phosphatase	4100 (normal)	3.0 (normal)

clinical features of this patient were similar to those previously described (Leroy *et al.*, 1971; Tondeur *et al.*, 1971; Wiesmann *et al.*, 1974).

In Hurler's disease, though suspicious features of the condition may already be recognised during the first 6 months of life, the classical syndrome does not develop until the end of the first year of life or later. A classical Hurler phenotype which presents in the first 6 months of life is more suggestive of I-cell disease or GM<sub>1</sub> gangliosidosis. Recurrent respiratory infections and suspicion of delayed development are the usual presenting features. Motor development is already delayed during the first few months and though most patients acquire the ability to sit with support by the age of 18 months, development rarely proceeds further. Social responses in contrast are relatively normal early on, but as development proceeds, self-feeding, the swallowing of solids, and pot-training are not achieved. Growth decelerates by one year of age and ceases by the age of 2. The clinical and radiological features become progressively more obvious and, apart from the gum hypertrophy, continue to resemble Hurler's disease. Recurrent respiratory infections are prominent and death usually occurs from pneumonia and congestive heart failure in early childhood.

In I-cell disease the primary defect is of ganglioside and glycoprotein metabolism with many striking acid hydrolase abnormalities which make screening and diagnosis possible. The plasma levels of activity of  $\alpha$ - and  $\beta$ -galactosidase, hexosaminidase,  $\alpha$ -mannosidase, fucosidase, and aryl sulphatase A are raised; the latter often by as much as 60 times the level of activity found in controls. Plasma acid phosphatase is normal. White blood cell acid hydrolases show normal levels of activity. In cultured skin fibroblasts the acid hydrolases, with the exception of acid phosphatase and  $\beta$ -glucosidase, are present in reduced amounts, about 10% of normal, and in the culture medium there is a ten-fold increase in the activities of these enzymes.

Initially these observations led to the 'leaky' lysosomal membrane hypothesis (Wiesmann *et al.*, 1971). However, Hickman and Neufeld (1972) showed that I-cell fibroblasts were able to pinocytose and retain exogenous lysosomal acid hydrolases from normal sources. They proposed that in I-cell disease the plasma membrane is unable to recognise the secreted exogenous acid hydrolases due to lack, or alteration, of a recognition marker in the hydrolase molecule and therefore cannot pinocytose them for incorporation into lysosomes. Thus I-cell disease is characterised by massive urinary secretion of sialyl oligosaccharides, increased acid hydrolase activity in plasma and the media of cultured fibroblasts, and the acid hydrolases secreted by cultured fibroblasts being more electronegative than intracellular hydrolases. Recently Strecker *et al.* (1976) have shown that patients with I-cell disease have a deficit of neuraminidase. Such a deficit would account for the above features by failure to remove n-acetylneuraminic acid from the oligosaccharide residue, thereby unmasking the recognition marker of the secreted glycoprotein, and is compatible with Hickman and Neufeld's hypothesis.

Prenatal diagnosis has been undertaken successfully (Aula *et al.*, 1975). Ultimately assay of the basic mutant enzyme will become available, but at present plasma aryl sulphatase A activity is a reliable screening test.

### Summary

A boy with fatal I-cell disease is reported. Defective ganglioside and glycoprotein metabolism is due to deficient neuraminidase activity.

I thank Professor O. H. Wolff and Dr A. D. Patrick for advice and encouragement, and Mrs E. Young for the enzyme assays.

### References

- Aula, P., Rapola, J., Autio, S. K., Raivio, K., and Karjalainen, O. (1975). Prenatal diagnosis and fetal pathology of I-cell disease (mucopolipidosis type II). *Journal of Pediatrics*, **87**, 221-226.
- Hickman, S., and Neufeld, E. F. (1972). A hypothesis for I-cell disease: defective hydrolases that do not enter lysosomes. *Biochemical and Biophysical Research Communications*, **49**, 992-999.
- Leroy, J. G., Spranger, J. W., Feingold, M., Opitz, J. M., and Crocker, A. C. (1971). I-cell disease: a clinical picture. *Journal of Pediatrics*, **79**, 360-365.
- Strecker, G., Michalski, J. C., Montreil, J., and Farriaux, J. P. (1976). Deficit in neuraminidase associated with mucopolipidosis II (I-cell disease). *Biomedicine*, **25**, 238-240.
- Tondeur, M., Vamos-Hurwitz, E., Mockel-Pohl, S., Dereume, J. P., Cremer, N., and Loeb, H. (1971). Clinical, biochemical and ultrastructural studies in a case of chondrodystrophy presenting the I-cell phenotype in tissue culture. *Journal of Pediatrics*, **79**, 366-378.
- Wiesmann, U. N., Vassella, F., and Herschkowitz, N. (1971). I-cell disease: leakage of lysosomal enzymes into extracellular fluids. *New England Journal of Medicine*, **285**, 1090-1091.
- Wiesmann, U. N., Vassella, F., and Herschkowitz, N. N. (1974). Mucopolipidosis (I-cell disease): a clinical and biochemical study. *Acta Paediatrica Scandinavica*, **63**, 9-16.

P. J. MILLA

Department of Child Health, Institute of Child Health, 30 Guilford Street, London WC1N 1EH.

## Use of the diving reflex to treat supraventricular tachycardia in an infant\*

Paroxysmal supraventricular tachycardia is a medical emergency in which the most commonly used therapy is DC shock or digitalis. The diving reflex in mammals has been known since the last century (Bert, 1870) and the subject has been more recently reviewed (Andersen, 1966). Its use in the treatment of supraventricular tachycardias has been reported by several authors (Wayne and Killip, 1967; Wildenthal *et al.*, 1975; Whitman *et al.*, 1977). We report a case of its use in an infant with a method not previously reported.

### Case report

A 26-day-old female infant was brought to hospital with a 2-week history of coryza. Shortly before admission she had vomited and was noted to be very pale. She was a 2-week post-term normal delivery and there had been no other problems since birth.

On examination she was markedly pale but active, and there was no cyanosis. The chest was clear and there was no hepatosplenomegaly or oedema. Heart sounds were normal and there were no added sounds, but the rate was approximately 250 beats/min. Systolic blood pressure was 60 mmHg. Peripheral pulses were good and no other abnormalities were found. After transfer to the intensive care unit, she was found to have a supraventricular tachycardia with a rate of 330 beats/min (Fig. 1). She was placed in the left lateral position, and while one ice cube was rubbed across the upper lip and bottom part of the nose, a second ice cube was rubbed across the nose from side to side. 30 to 45 seconds later, when the baby was starting to splutter, the heart rate dropped to 100 beats/min, recovering 10

\*See also Correspondence, p. 520. Ed.