

- Duehr, P. A. (1955). Herpeszoster as a cause of congenital cararact. *American Journal of Ophthalmology*, **38**, 157.
- Feldman, G. V. (1952). Herpeszoster neonatorum. *Archives of Disease in Childhood*, **27**, 126.
- Fox, M. J., Krumbiegel, E. R., and Teresi, J. L. (1948). Maternal measles, mumps and chickenpox as a cause of congenital abnormalities. *Lancet*, **1**, 746.
- Laforet, E. G., and Lynch, C. L. (1947). Multiple congenital defects following maternal varicella. *New England Journal of Medicine*, **236**, 534.
- McKendry, J. B. J., and Bailey, J. D. (1973). Congenital varicella associated with multiple defects. *Canadian Medical Association Journal*, **108**, 66.
- Newman, C. G. H. (1965). Perinatal varicella. *Lancet*, **2**, 1159.
- Rinvik, R. (1969). Congenital varicella encephalomyelitis in surviving newborn. *American Journal of Diseases of Children*, **117**, 231.
- Savage, M. O., Moosa, A., and Gordon, R. R. (1973). Maternal varicella infection as a cause of fetal malformations. *Lancet*, **1**, 352.
- Sever, J., and White, L. R. (1968). Intrauterine viral infections. *Annual Review of Medicine*, **19**, 471.
- Siegel, M., Fuerst, H. T., and Peress, N. S. (1966). Comparative fetal mortality in maternal virus diseases. *New England Journal of Medicine*, **274**, 768.

J. E. H. BRICE

*Department of Child Health, University of Dundee, Ninewells Hospital and Medical School, Dundee DD1 9SY.*

## Blue double light

### Improved method of phototherapy

Phototherapy with white light reflected onto one side of the patient has reduced the number of exchange transfusions in newborn infants with rhesus haemolytic disease (Reid *et al.*, 1972; Roth-Maintz and Schellong, 1973; Shennan, 1974; Møller and Ebbesen, 1975). Phototherapy with white light reflected onto both sides of a jaundiced newborn infant has been stated to be highly effective (Isenberg and Fisch, 1973). We have developed a system of reflecting blue light onto both sides of an infant with the hope of further reducing the number of exchange transfusions necessary, and have compared the efficiency of this blue double light with traditional single white light in newborn infants with rhesus haemolytic disease.

#### Methods

The blue double light was arranged with 6 blue fluorescent bulbs (Westinghouse, special blue, F20T12/BB) 53 cm above and 48 cm beneath a translucent Perspex plate and an airfilled, translucent, disposable mattress (see Fig.). Conventional white light therapy was provided from a unit of 6 fluorescent bulbs (Philips TL 20W/33) 60 cm above mattress level (Møller and Ebbesen, 1975).

Phototherapy was given continuously from the first 1-3 hours of life until serum bilirubin levels fell consistently for at least one day below 204  $\mu\text{mol/l}$  (11.9

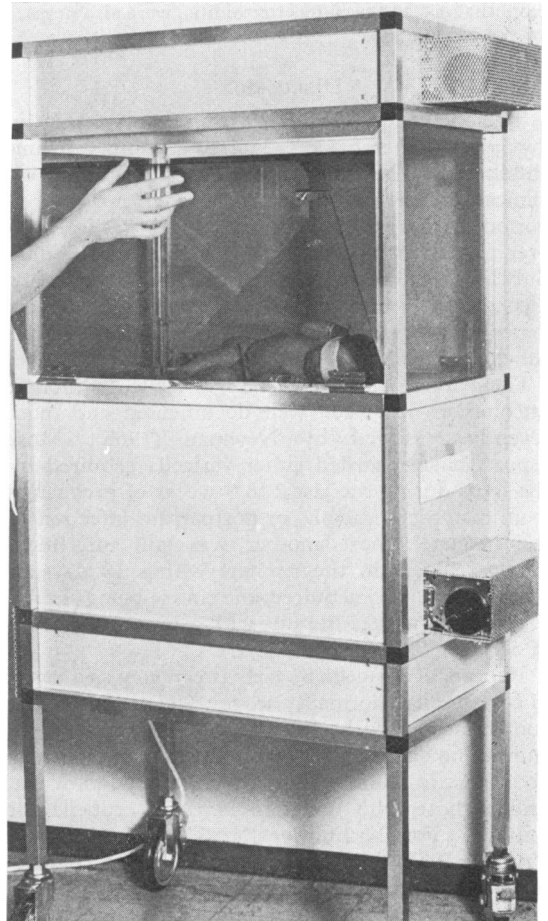


FIG.—Arrangement for phototherapy with blue double light. Observation of the infant is allowed by shutters of orange coloured, translucent Perspex plates. The bulbs are separated from the room of the infant by clear, translucent Perspex plates and cooled by a fan.

mg/100 ml). Capillary blood was collected at 3- or 6-hour intervals for determination of serum bilirubin levels by a spectrophotometric method. Exchange transfusions were performed soon after birth if cord serum bilirubin levels exceeded 68  $\mu\text{mol/l}$  (4.0 mg/100 ml) or cord blood Hb levels were less than 11.9 g/dl. These exchange transfusions were called early exchange transfusions and were performed within the first 12 hours of life. Exchange transfusions performed after that period were called late exchange transfusions and were carried out in all cases if serum bilirubin levels reached 340  $\mu\text{mol/l}$  (20 mg/100 ml). The umbilical vein was catheterized and the infant's blood was exchanged with 170 ml/kg citrated, freshly-drawn blood. Thereafter kanamycin was administered for 3 days.

### Patients

Only rhesus-positive infants with strongly positive direct Coombs's test born of rhesus-negative mothers were included in the study. None of the mothers had received anti-D prophylaxis. Phenobarbitone was not administered to the mothers before birth nor to the infants after birth. Infants with Apgar scores  $>7$  at 5 minutes after birth, and those with respiratory distress symptoms and apnoea were excluded. All patients received a conventional formula feed (Semper) at 4- to 6-hour intervals. Consent was obtained from the parents before phototherapy.

During the first 12 months of the study 42 infants (23 boys, 19 girls) were given phototherapy with white light and during the last 8 months 28 infants (16 boys, 12 girls) were treated with the blue double light regimen. The two groups were comparable as to gestational age and birthweight, and Hb and cord serum bilirubin levels in cord blood (Table).

### Results

In the blue double light group 12 of the 28 infants (43%) received early exchange transfusions, and in the white light group 16 of the 42 infants (38%) received early exchange transfusions. These early exchange transfusions were regarded as 'inevitable', as it is only the number of late exchange transfusions which might be reduced by phototherapy. In the blue double light group, 25 of the 28 infants did not receive late exchange transfusion. The remaining 3 infants received 3 exchange transfusions (one each). In the white light group 25 of the 42 infants did not receive late exchange transfusion, and the remaining 17 infants received a total of 27 exchange

transfusions (10 infants received one late exchange transfusion each and 7 infants two or more transfusions each). The difference between the two groups was significant ( $P < 0.01$ ,  $\chi^2$  test). All exchange transfusions were performed during the course of phototherapy, which averaged 82 hours in the blue double light group and 89 hours in the white light group.

Severe anaemia was expected to develop mainly in the infants exposed to the blue light, since fewer exchange transfusions might have led to a lessened elimination of rhesus antibodies, but no infant required blood transfusions. Transient macular rashes were observed in 2 infants from both groups. No side effects were observed owing to the airfilled, disposable, translucent mattresses. Though it has been reported that infants treated with double light may develop fever and irritability (Healy, 1974), none did so.

### Discussion

Although the immediate side effects of phototherapy were of minor importance, and long-term effects have also been considered to be slight (Behrman, 1974), the possibility of long-term effects cannot be dismissed. Therefore, intense phototherapy as provided by blue double light should only be used in infants threatened by the hazards of exchange transfusions and kernicterus.

We conclude that the blue double light arrangement may be superior to the conventional type of phototherapy in the management of infants with rhesus haemolytic disease.

TABLE

Comparison of neonates with rhesus haemolytic disease who received blue double light therapy and those who received conventional treatment with white light

	Blue double light	Conventional white light
No. of patients	28	42
Ratio male/female	16/12	23/19
Birthweight (g)		
Mean $\pm$ SD ( $P > 0.4$ )	3010 $\pm$ 410	3020 $\pm$ 630
Gestational age (w)		
Mean $\pm$ SD ( $P > 0.2$ )	38.1 $\pm$ 1.5	37.7 $\pm$ 1.4
Cord blood Hb (g/dl)		
Mean $\pm$ SD ( $P > 0.4$ )	14.8 $\pm$ 5.8	14.5 $\pm$ 4.2
Cord serum bilirubin ( $\mu$ mol/l)		
Mean $\pm$ SD ( $P > 0.4$ )	63 $\pm$ 31	60 $\pm$ 27
Number of previous pregnancies:	(3.7 $\pm$ 1.8 mg/100 ml)	(3.5 $\pm$ 1.6 mg/100 ml)
None	2 (7%)	1 (2%)
1	9 (32%)	11 (26%)
2	7 (25%)	14 (33%)
3+	10 (36%)	16 (38%)
Possible ABO immunization	3 (11%)	7 (17%)
Delivery by caesarean section	2 (7%)	6 (14%)

**Summary**

In newborn infants with rhesus haemolytic disease the effect of phototherapy with blue light (28 cases) on both sides of the infant was compared with the effect of traditional white light phototherapy on one side of the infant (42 cases). The number of exchange transfusions performed after the first 12 hours of life was significantly lower in the blue double light group. It is concluded that the application of blue double light may be a superior means of applying phototherapy in rhesus haemolytic disease.

## REFERENCES

- Behrman, R. (1974). Preliminary report of the committee on phototherapy in the newborn infant. *Journal of Pediatrics*, **84**, 135.
- Healy, C. E. (1974). Responses to phototherapy for neonatal hyperbilirubinemia. *Journal of Pediatrics*, **84**, 458.

- Isenberg, J. N., and Fisch, R. O. (1973). Double-light phototherapy for neonatal hyperbilirubinemia. *Journal of Pediatrics*, **83**, 116.
- Møller, J., and Ebbesen, F. (1975). Phototherapy in newborn infants with severe rhesus hemolytic disease. *Journal of Pediatrics*, **86**, 135.
- Reid, M. McC., McClure, G., Marks, E., and Elwood, J. H. (1972). Phototherapy in rhesus haemolytic disease. *Lancet*, **1**, 879.
- Roth-Maintz, G., and Schellong, G. (1973). Phototherapie bei Rh-bedingtem Morbus haemolyticus neonatorum. *Monatsschrift für Kinderheilkunde*, **121**, 467.
- Shennan, A. T. (1974). The effect of phototherapy on hyperbilirubinemia of rhesus incompatibility. *Pediatrics*, **54**, 417.

FINN EBBESEN and JØRN MØLLER\*

*Department of Neonatology, Rigshospitalet, University of Copenhagen, Denmark.*

---

\*Correspondence to Dr. Jørn Møller, Kronprinsessegade 40, 1306 København K., Denmark.