

preoperatively, which shows the importance of histology on any small tumour excised. Histiocytomata are rare in children (Evans, 1966). In a series of 39 cases of histiocytic tumours in children below the age of 16 years reported by Kauffman and Stout, 19 were classified as benign fibrous xanthomata (i.e. tumours which show xanthoma-like cells as an essential component) and 12 were benign histiocytomata. 6 of the patients with benign histiocytomata were aged below 1 year, 2 having a history from birth. No other cases of benign histiocytoma have apparently been recorded occurring on toes, below the age of 1 year.

### Summary

Histiocytomata are well-known tumours in adults but rare in children. Two cases have presented with swellings on the toes under 1 year. There may be recurrence of the tumour if excision is inadequate.

We wish to thank Mr. F. C. Durbin for allowing us to present these cases; also Dr. Stewart Smith and Dr. A. Caldwell for their assistance in interpreting the pathological appearances.

### REFERENCES

- Dawson, E. K. (1948). Sclerosing angioma: a non-melanotic pigmented tumour of skin. *Edinburgh Medical Journal*, **55**, 655.
- Evans, R. W. (1966). *Histological Appearances of Tumours*, 2nd ed., p. 12. Livingstone, Edinburgh.
- Gross, E. R., and Wolbach, S. B. (1943). Sclerosing hemangiomas: their relationship to dermatofibroma, histiocytoma, xanthoma and to certain pigmented lesions of the skin. *American Journal of Pathology*, **19**, 533.
- Kauffman, S. L., and Stout, A. P. (1961). Histiocytic tumors (fibrous xanthoma and histiocytoma) in children. *Cancer (Philadelphia)*, **14**, 469.

D. SPENCER and J. D. WRIGHTON\*

*Department of Pathology, Wycombe General Hospital, High Wycombe and Princess Elizabeth Orthopaedic Hospital, Exeter.*

\*Correspondence to Mr. J. D. Wrighton, F.R.C.S., The Royal Cornwall Hospital (City), Truro, Cornwall.

## Glycogen Storage Disease, Type VIII\*

Glycogenolysis occurs in a sequential series of reactions involving hydrolysis of  $\alpha 1 \rightarrow 4$  and  $\alpha 1 \rightarrow 6$  glycosidic linkages, resulting in the liberation of phosphorylated and free glucose. One enzymatic component of this system, phosphorylase, is

\*This work was supported in part by Training Grant NIH 1 TO1 AMO-5680-01 DM from the National Institutes of Health.

activated by a kinetic cascade mechanism mediated by cyclic AMP as a consequence of hormonal action. Since 1966 (Hug, Schubert, and Chuck, 1966b), disease states characterized by phosphorylase deficiency and glycogen accumulation have been shown to occur from defects in phosphorylase kinase, in the 3',5'-AMP dependant kinase system (Hug *et al.*, 1970a), and from absence of phosphorylase.

The diagnosis of these genetic enzymopathies is dependent upon the delineation of the biochemical defect, the accumulation of glycogen of normal structure and the occurrence of certain clinical symptoms. Recent investigations (Huijing and Fernandes, 1969) have employed leucocyte phosphorylase assays to establish the diagnosis. This report presents studies of carbohydrate homeostasis in a young girl with a defective hepatic phosphorylase system and suggests the unreliability of the leucocyte assay as an indicator of hepatic phosphorylase activity.

### Case Report

A 17½-month-old black girl was seen with a referral diagnosis of hepatomegaly secondary to glycogen storage disease. She was the product of a term gestation with an uncomplicated neonatal period. The patient was admitted to hospital at 3 months of age because of diarrhoea and dehydration. At 7 months of age, the mother noticed the onset of abdominal enlargement which progressed to the present time. She was admitted to Tampa General Hospital at age 16 months for diagnostic evaluation; fasting blood sugars ranged from 20–40 mg/100 ml, with normal postprandial blood sugar values, and x-rays of the chest and skull were normal. A liver biopsy showed enlarged cells laden with glycogen and without signs of periportal fibrosis. There was no family history of liver disease, disorders of carbohydrate metabolism (including diabetes), or other significant family illnesses.

Physical examination revealed a small girl with a very protuberant abdomen. The significant physical finding was a massively enlarged liver which extended to the iliac crest; it was diffusely enlarged, non-nodular, and firm to palpation. Haematological evaluation revealed a modestly prolonged clotting time. Blood sugar determinations throughout 24-hour periods indicated on some occasions hypoglycaemia after fast periods of up to 10 hours. Liver function tests indicated increased levels of the transaminase enzymes and a marked rise in alkaline phosphatase; uric acid level was high normal for our laboratory. A modest rise of blood lipids was also noted (570 mg/100 ml). Glucose tolerance tests were normal, showing a normal insulin response and a concordant depression of blood lactate (Table I). A normal rise in blood glucose occurred after glucagon stimulation (1 mg).

TABLE I  
Carbohydrate Homeostasis in Patient

A: Basal Studies				
Time (min)	Glucose Tolerance			Glucagon Stimulation
	Blood Glucose (mg/100 ml)	Lactate (mg/100 ml)	Insulin	Blood Glucose (mg/100 ml)
0	86	0.9	—	30
30	153	0.1	—	125
60	143	0.1	—	—
90	—	—	—	—
120	95	0.1	36 U/ml	—
180	100	0.1	—	—

B: Diazoxide Therapy		
Time (min)	Glucose Tolerance	
	Blood Glucose (mg/100 ml)	Insulin (U/ml)
0	35	11
30	177	19
60	129	33
120	195	46
180	110	29

of the biopsy specimen revealed raised glycogen content of 12%; liver phosphorylase levels were between 10 and 15% of the normal values obtained in our laboratory (Table IIA). Enzymatic analyses for amylo-1,6-glucosidase, acid phosphatase, and glucose-6-phosphatase were within normal limits.

The patient was given a trial of therapy with diazoxide at a dosage of 4 mg/kg of body weight in 3 divided doses for 1½ months. Significant findings after this regimen were that on all occasions normal leucocyte phosphorylase levels were obtained (Table IIB); however, no change was noted in the degree of hepatomegaly. Diazoxide produced a diabetic-like glucose tolerance test without concordant suppression of insulin release; in addition, fasting hypoglycaemia did not occur.

#### Methods and Results

Glycogen was extracted from erythrocytes according to the method of Sidbury *et al.*, (1961) and quantitated by the anthrone method. The patient's red blood cells contained 126.5 µg glycogen/g Hb. The iodine

Red cell glycogen analysis revealed a value in the high normal range. Leucocyte enzyme assays indicated depressed phosphorylase activity and, on some occasions, normal leucocyte phosphorylase levels; however, amylo-1,6 glucosidase activity was always normal. Histological examination of the liver biopsy revealed infiltration of liver cells with material positive to Best's carmine and PAS; diastase treatment resulted in disappearance of these granules. Biochemical examination

TABLE II  
Phosphorylase Activity, in Patient and Normal Subject

A: Liver Phosphorylase (µM Pi liberated/g protein)		
	Patient	Normal Subject
Time:		
t = 20 min	10.21	72 ± 14.7
t = 30 min	13.79	81 ± 18.9
Specific activity:	0.48 µM Pi/g protein per min	3.15 ± 0.67 µM Pi/g protein per min

B: Leucocyte Phosphorylase (µM Pi/mg protein per min)			
		Normal	(Normal, literature)
Pre-diazoxide	(1) 0.44 ± 0.01 (2) 0.07 ± 0.03	0.198 ± 0.043	0.27-1.15*
Post-diazoxide	(1) 0.57 ± 0.02 (2) 1.09 ± 0.15	—	—

\**Biochimica Biophysica Acta* (1967), 148, 601.

absorption method (Sidbury *et al.*, 1961) gave a peak absorption at 460 m $\mu$ .

Leucocytes were isolated by sedimentation at 37 °C in a heparinized syringe containing 1 ml 6% dextran/10 ml whole blood. The cells were washed twice with 0.15 M NaF, followed by two washings of 0.05 M NaF. The cells were suspended in Tris buffer, pH 6.2, and either assayed immediately or frozen after the addition of 0.1 ml of 0.1 M NaF/ml of suspended cells. No activity was lost by freezing.

Cells to be assayed were sonicated for 2 minutes at 0° C and the lysate assayed for phosphorylase activity.

The reaction catalysed by phosphorylase is reversible *in vitro* at pH 6.2 and is the basis for this assay method (Sutherland, 1955). The reaction is quenched by incubation at 100 °C. Enzymatic activity was measured by following the release of inorganic phosphate (P<sub>i</sub>) by the Fiske-Subbarow method.

The liver homogenate was prepared by hand homogenization in 0.1 M NaF at 0 °C and assayed by the same method (Sutherland, 1955). Glucose-6-phosphatase and acid phosphatase were also assayed. Protein content was determined by the Lowry procedure.

### Discussion

In 1959 Hers initially described 3 patients characterized by hepatic glycogen accumulation and phosphorylase deficiency. Since then several reports (Hug *et al.*, 1966a) indicated that this clinical picture might be produced by several defects within the phosphorylase cascade mechanism. Clinical distinctions between 2 of these—namely, Type VIII and Type IX glycogen storage disease—are based on single case reports in which distinguishing characteristics have been the presence of mental retardation and increased catecholamine excretion. Further delineation of these two types was suggested to be dependent upon the *in vivo* and *in vitro* responses to glucagon or cyclic AMP derivatives.

Hug and coworkers (1966b) have suggested that Type VIII disease is associated with a defect in the external control of the phosphorylase system (i.e. normal function can be restored with glucagon treatment), with associated incomplete activation of the adenyl cyclase system in the brain, resulting in derangement of central nervous system function. Type IX glycogen storage disease shows an inadequate response to glucagon administration with normal mentation, and phosphorylase activity may be restored *in vitro* by the administration of cyclic AMP or its substituted derivatives. The patient presented in this report fits the classification described for Type VIII glycogen storage disease with regard to glucagon response; however, she exhibits normal mental capacities and has normal catecholamine excretion. It is suggested that the construction of clinical phenotypes requires further

case studies, and that clinical delineation is not possible if these latter two physical findings are the sole criteria.

Schwartz *et al.* (1970) and Huijing and Fernandes (1969) illustrated the apparent usefulness of leucocyte phosphorylase assays to make biochemical diagnoses in this group of diseases. The studies presented in this report suggest that this method is not a constant indicator of the hepatic phosphorylase system. Our observations support the contention of Hug *et al.* (1970b) that the precise diagnosis is dependent on the examination of liver tissue.

Diazoxide therapy was initiated since it inhibits insulin release, increases adrenal medullary secretion of epinephrine and inhibits the cyclic AMP phosphodiesterase activity (Rennert and Mukhopadhyay, 1968); these should act in concert to increase intracellular cyclic AMP. In this patient fasting hypoglycaemia was ameliorated; however, insulin suppression did not occur. No reduction in hepatomegaly was evidenced based on clinical examination and liver scan with technicium.

### Summary

The biochemical, clinical, and histological findings of phosphorylase deficiency in a 17½-month-old girl have been presented. According to present classifications her defect is compatible with Type VIII glycogen storage disease. Leucocyte phosphorylase assays in this case were not found to exemplify accurately the hepatic phosphorylase system.

### REFERENCES

- Hers, H. G. (1959). Études enzymatiques sur fragments hépatiques: application à la classification des glyco-génoses. *Revue Internationale d'Hépatologie*, **9**, 35.
- Hug, G., Garancis, J. C., Schubert, W. K., and Kaplan, S. (1966a). Glycogen storage disease, types II, III, VIII, and IX. *American Journal of Diseases of Children*, **111**, 457.
- Hug, G., Schubert, W. K., and Chuck, G. (1966b). Phosphorylase kinase of the liver: deficiency in a girl with increased hepatic glycogen. *Science*, **153**, 1534.
- Hug, G., Schubert, W. K., and Chuck, G. (1970a). Loss of cyclic 3' 5'-AMP dependent kinase and reduction of phosphorylase kinase in skeletal muscle of a girl with deactivated phosphorylase and glycogenesis of liver and muscle. *Biochemical and Biophysical Research Communications*, **40**, 982.
- Hug, G., Schubert, W. K., and Chuck, G. (1970b). Liver glycogenesis and phosphorylase kinase deficiency. *American Journal of Human Genetics*, **22**, 484.
- Huijing, F., and Fernandes, J. (1969). X-chromosomal inheritance of liver glycogenesis with phosphorylase kinase deficiency. *American Journal of Human Genetics*, **21**, 275.
- Rennert, O. M., and Mukhopadhyay, D. (1968). Diazoxide in Von Gierke's disease. *Archives of Disease in Childhood*, **43**, 358.
- Schwartz, D., Savin, M., Drash, A., and Field, J. (1970). Studies in glycogen storage disease. IV. Leukocyte phosphorylase in a family with type VI GSD. *Metabolism: Clinical and Experimental*, **19**, 238.
- Sidbury, J. B., Jr., Cornblath, M., Fisher, J., and House, E. (1961). Glycogen in erythrocytes of patients with glycogen storage disease. *Pediatrics*, **27**, 103.

Sutherland, E. W. (1955). Polysaccharide phosphorylase, liver. In *Methods in Enzymology*, Vol. I, p. 215. Ed. by S. P. Colowick and N. O. Kaplan. Academic Press, New York.

M. LUDWIG, S. WOLFSON, and O. RENNERT\*  
*The Department of Pediatrics, University of Florida  
 College of Medicine, Gainesville, Florida 32601,  
 U.S.A.*

\*Correspondence to Dr. O. Rennert.

## Direct Current Cardioversion in a Case of Congenital Atrial Flutter

The congenital type of atrial flutter has a poor prognosis when unresponsive to digoxin (Moller, Davachi, and Anderson, 1969). Recorded experience with cardioversion is limited but it has been suggested that this type of flutter is refractory to electric countershock (Rodriguez-Coronel, Sueblingvong, and Hastreiter, 1968).

We report an infant with congenital heart defects and congenital atrial flutter who appeared resistant to digoxin and  $\beta$ -blockade (practolol) but readily reverted to sinus rhythm with direct current (DC) cardioversion.

### Case Report

This was the second pregnancy of a 25-year-old whose health was good until mild hypertension developed at term. Labour was induced at 40 weeks, and the fetal heart was noted to be rapid and irregular. A mature female infant weighing 3.8 kg was delivered by emergency caesarean section. No meconium staining was evident, and the Apgar score at one minute was 9. The infant remained active, sucked well, and was pink breathing air.

The apex beat was consistently 180–200/minute. No cardiac murmurs were heard at this time and there were no signs of respiratory distress. X-ray showed slight cardiomegaly and clear lung fields. ECG showed atrial flutter with varying AV block and a ventricular rate around 180/minute.

An attempt was made to control the ventricular rate using digoxin orally. A total dose of 0.3 mg over the first 24 hours was given, and 0.075 mg daily thereafter. After 3 days there was no change in the underlying arrhythmia or the ventricular rate (Fig.). At this time a soft systolic murmur became audible at the left sternal edge.

At the age of 4 days cardiac catheterization revealed an atrial septal defect with a pulmonary-systemic flow ratio of 2 : 1 and a minor degree of aortic coarctation. During

the procedure the atrial flutter reverted to sinus rhythm for two short periods.

At 5 days digoxin was stopped. After 24 hours, and with continuous ECG monitoring, practolol was given twice within one hour by slow i.v. injection in a dose of 0.5 mg diluted in 10 ml saline. No effect was noted on the heart rate or rhythm. Oral practolol 2.2 mg/kg twice daily was given and increased to four times daily without effect on rate or rhythm (Fig.).

By 10 days the baby's condition was deteriorating with tachypnoea and feeding difficulty. The liver was palpable two fingers' breadth below the costal margin. X-ray revealed increasing cardiomegaly. DC cardioversion was, therefore, attempted.

No anaesthetic was given. Adult electrodes (9 cm diameter) were placed on the right midsternal border and on the apex with about nine-tenths of the surface area of the paddles masked by insulating tape. A shock of 10 watt-seconds was given from a Lown cardioverter. There was immediate reversion to sinus rhythm with an

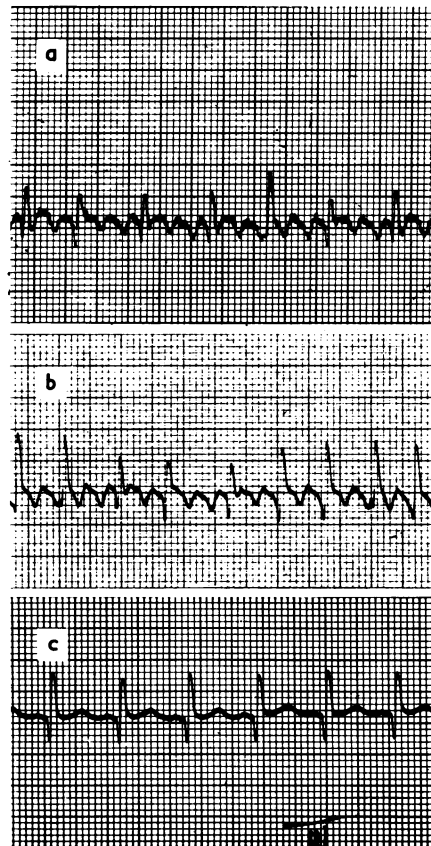


FIG.—Electrocardiogram (lead III) in congenital atrial flutter: effects of treatment; (a) on digoxin, (b) on practolol, and (c) after cardioversion.