

EPIDERMOLYSIS BULLOSA HEREDITARIA 'LETALIS' : REPORT OF A CASE SURVIVING FOR TWO AND A HALF YEARS

BY

HENRY K. SILVER

From the Department of Pediatrics, Yale University School of Medicine, New Haven, Connecticut

(RECEIVED FOR PUBLICATION JANUARY 22, 1957)

Epidermolysis bullosa is a chronic hereditary disease of unknown aetiology involving the skin and mucous membranes. It is characterized by the formation of multiple superficial vesicles and bullae which develop spontaneously or as a result of minimal trauma. The disease may occur in varying grades of severity but there is one form with distinct characteristics which has been classified as epidermolysis bullosa hereditaria letalis. In all other cases it has been uniformly fatal within the first few months of life. The purpose of this paper is to report a patient who has this type of the disease but is still alive at the age of 30 months.

Case Report

S.B. was born at term at the Grace-New Haven Community Hospital after an uneventful pregnancy. She was the third child of a 24-year-old white woman whose serological tests for syphilis were negative. The first pregnancy had resulted in a mentally retarded female with a convulsive disorder and the second in a female with congenital heart disease. Inquiry regarding the occurrence of a similar skin condition in the parents, grandparents, great-grandparents and other members of the family failed to reveal any significant abnormalities in any of them. There was nothing in the story of either parent to accord with the fact that all their four children had congenital abnormalities. At birth the patient appeared normal except for numerous bullous and denuded areas on various parts of her body, including the dorsum of the right foot, right calf, several toes, lips and the mucous membranes of the mouth and nose.

Immediately after birth, the infant was transferred from the delivery room to a nursery and strictly isolated. She was placed in an open crib lined with plastic sheet-

ing. She was kept unclothed with the covers raised above her body in an attempt to minimize irritation to the skin. Body warmth was maintained with the aid of a goose-necked heat lamp. She was handled as little as possible, and then only by persons who wore gown, mask and sterile gloves. Within the first six hours of life the first of several antibiotics was started in an attempt to prevent and eliminate secondary infections of the open lesions. Various methods of feeding were tried, including medicine dropper, gavage, nipple and medicine glass. In spite of these measures new lesions appeared on the trunk, head, extremities and mucous membranes. The lesions would begin as localized areas of erythema which became bullous, sloughed and would then gradually granulate and epithelialize. When one of the bullae broke, a crust formed which sealed off the denuded portion of the skin so that fluid loss from the lesions was never very extensive. Scarring did not occur although a residual area of erythema might persist for many weeks. Bullae in the mouth were frequently haemorrhagic, while those of the skin occasionally contained blood-tinged fluid.

Because of the known severity of the disease process and the expected fatal outcome, it was decided to try various hormones in an attempt to alter the course of the disease. On the thirty-second day of life she was started on a preparation of conjugated oestrogens, 0.625 mg. daily. One week later this was discontinued and hydrocortisone, 20 mg. every eight hours, orally, was given. Four weeks later the dosage of hydrocortisone was increased to 20 mg. every four hours. After 10 days on this dosage she was gradually weaned from this drug. At the age of 2½ months she was given testosterone propionate, 5 mg. daily, for one week. Although fewer lesions seemed to be appearing during the second month of life, hormone therapy did not produce any marked change in her course.

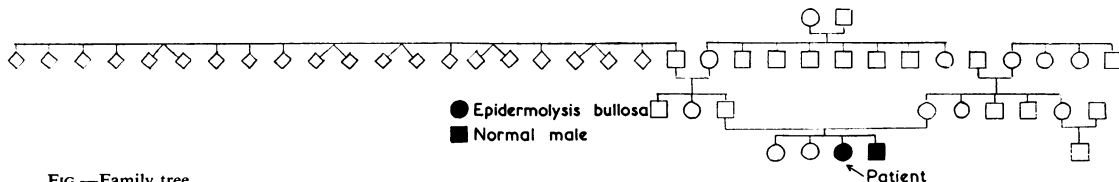


FIG.—Family tree.

At 9 weeks of age an abscess developed on the right ankle. This required surgical drainage and then subsided without complication. Non-haemolytic staphylococcus was cultured from the abscess.

For the next nine months her condition remained essentially unchanged. New lesions continued to appear which would go through a full cycle and then heal without leaving any scars. When she was 7 months old the aseptic technique and strict isolation were gradually liberalized in order to permit freer handling and increased social contact. During the summer months she was kept in an air-conditioned room to prevent marked swings in environmental temperature. At 10 months of age when her condition seemed stable she was transferred to a nursing home.

For the next 20 months the disease process continued to be active. New lesions appeared on all parts of the body and in the mouth. Occasionally these would become secondarily infected and as a result almost continuous antibiotic therapy was necessary. Several nails were lost completely and in these areas epithelialization occurred but no deformities resulted. Development was slow although she was able to say a few words. Her spirits were usually good but she became irritable when handled by strangers. Her weight gain was relatively slow. She had been found to have an iron-deficiency anaemia at the age of 1½ years and had been given treatment with supplemental iron. No special isolation precautions were being used. At the age of 2½ years her condition continued to be essentially unchanged.

When the patient was 21 months old the mother gave birth to a 3,120 g. boy who also had epidermolysis bullosa. At birth several denuded areas were present on the lower extremities. During the first few days of life he developed new lesions on the extremities, face and in the mouth, which were identical with those that his sister had had. When these eventually cleared there was no residual scarring of the skin. He was started on prophylactic antibiotics shortly after birth and received the same type of nursing care that was administered to his sister. In addition he received cortisone, 100 mg. daily, from the third to twentieth day of life, and prednisone, 20 mg. daily, for an additional six days. Although his disease was extensive, it was not felt to be as severe as it had been in his sister. At the age of 2 months he developed a staphylococcus pneumonia which responded well to chloramphenicol and novobiocin. After recovery from this infection he was transferred to a nursing home.

Discussion

Epidermolysis bullosa was first described by von Hebra in 1870 and by Fox in 1879 and was given its present name by Köbner in 1886. It usually affects infants at birth or shortly thereafter, but may not appear for months or even years. The disease is characterized by multiple vesicles or bullae which are most apt to occur at the sites of pressure or trauma. The bullae may be filled with a clear serous material or with blood-tinged fluid which is

sterile on culture. In certain forms of epidermolysis bullosa the mucous membranes of the alimentary and respiratory tracts are involved. The finger- and toe-nails are frequently thickened and deformed or they may be absent. In many, but not all of the cases, Nikolsky's sign (detachment of the upper layers of the skin by trauma) may be present.

Several theories as to the aetiology of the disease have been postulated. These include endocrine imbalance, increased irritability of the cutaneous vascular system (Elliot, 1900), absence or deficiency of elastic fibres in the papillary and subpapillary layers of the skin (Engman and Mook, 1906), a disturbance of the vascular system with some inherent defect of the vessel wall itself (Winer and Orman, 1945) and an altered hyaluronidase-heparin ratio (Langhof, 1952). However, the most widely accepted theory is that there is some inherited intrinsic disturbance of the structure of the skin.

The pathological findings have been quite variable. Herlitz (1935) reported that the skin was unusually thin and showed degeneration of the elastic fibres with rudimentary sweat glands and hair follicles. Engman and Mook (1906), Matheson and Rosner (1949), Siemans (1937) and Schäffer (1951) also concluded that the superficial layers of the skin contained deficient elastic tissue, while Leland and Hirschl (1954) observed degeneration of the collagen fibrils of the skin. On the other hand Lamb and Halpert (1947) found the hair follicles, sebaceous and sweat glands and collagenous bundles in the skin to be normal, and Lewis, Steven and Farquhar (1955) noted apparently normal elastic elements in two fatal cases.

Epidermolysis bullosa has been divided into four main forms (Herlitz, 1935; Cockayne, 1933; and Touraine, 1942).

(1) **Simple, Non-scarring Type.** This is a simple non-scarring type which appears in infancy or childhood in otherwise normal children and is inherited as a Mendelian dominant trait. This form is manifested by superficial bullae which develop mainly over the extremities as a result of friction or trauma. The bullae heal within a few days without scarring or pigmentation. The mucous membranes and nails are not involved. The disease is usually self-limited and tends to improve markedly or to disappear completely at puberty.

(2) **Mendelian Dominant Type.** A Mendelian dominant dystrophic type is transmitted by affected members of either sex and appears at birth or soon afterwards in children who otherwise have normal physical and mental development. The lesions are particularly severe on the hands or toes and over

Type	Mendelian Inheritance	Age of Onset	Site of Lesions				Persistence of Lesions	Residual Scarring	Physical Development	Mental Development	Prognosis
			Extremities	Mucous Membranes	Nails	Trunk					
Simple or non-scarring	Dominant	Infancy or childhood	+	0	0	0	Few days	0	Normal	Normal	Clears at puberty
Dystrophic (dominant)	Dominant	Birth or early infancy	+	±	+	±	Prolonged	+	Normal	Normal	May clear at puberty
Dystrophic (recessive)	Recessive	Birth or early infancy	+	+	+	±	Prolonged	+	Retarded	Retarded	Most die in childhood
Lethal (Herlitz)	Recessive	Birth or neonatal	+	+	+	+	Prolonged	0			Most die in early infancy
Present case	Unknown	Birth	+	+	+	+	Prolonged	0	Retarded	Retarded	Alive at 2½ years

other areas liable to trauma or pressure. The lesions may heal without scarring, but in many instances thin atrophic scars are formed which contain small epidermal cysts. Finger- and toe-nails are often lost and on growing back may be thickened or deformed. The mucous membranes may be involved and when lesions in these areas heal a leukoplakia-like atrophy results. This form of the disease sometimes improves spontaneously at puberty but the abnormal traumatic response may persist throughout life.

(3) Recessive Dystrophic Type. A recessive dystrophic type appears at or shortly after birth and affects children who subsequently have poor physical and mental development. Bullae are formed which are often large and filled with blood-stained fluid. On healing, keloidal scars, contractures and pigmentation may occur. The finger- and toe-nails and the mucous membranes of the alimentary and respiratory tracts are frequently affected. There may be associated congenital defects of teeth, nails and hair. Many of these children die in infancy and it is very unusual for any to reach maturity.

(4) Lethal (Herlitz) Type. A lethal (Herlitz) type is transmitted as a Mendelian recessive and appears at birth or shortly thereafter. It is characterized by the appearance of multiple superficial bullae not specifically related to trauma which often contain blood-stained fluid. There is marked deformity of the finger- and toe-nails and some of these nails may be missing. The mucous membranes are uniformly involved with bullous lesions which break and leave ulcerations. Nikolsky's sign may be present. The lesions heal without scarring. Skeletal atrophy may

occur near areas of skin showing localized congenital defects.

Herlitz (1935) first classified this as a distinct type and called it 'epidermolysis bullosa hereditaria letalis'. He reported eight cases of his own and collected 14 others from the literature. In 1954 Leland and Hirschl reviewed this form of the disease and found a total of 34 cases. They added two more of their own in twin mulatto females. Since then other cases have been reported by Frank and Kern (1954), Calnan (1954-55), Lewis *et al.* (1955) (three cases), Henderson (1955) (four cases) and Lucini (1955), making a total of 46 cases.

The patient herein reported had the main features of the variety of epidermolysis bullosa first described by Herlitz. Her disease started at birth and was characterized by vesicles and bullae involving the skin and mucous membranes. Many of the bullae were haemorrhagic and those on the buccal mucosa often became ulcerated. Severe lesions occurred around the finger- and toe-nails and this resulted in marked deformity or complete destruction of these structures. In spite of the extensive involvement of the skin, lesions healed without scarring.

The lethal form of epidermolysis bullosa was originally thought to result in death within the first three or four months of life. However, several cases, including those of Calnan (1954-55) and Henderson (1955), have lived for at least six months, and one of the patients reported by Kagen, Williams, Giffin and Wiley (1952), which in other respects appeared to be a typical case of epidermolysis bullosa hereditaria letalis, lived to the age of 16 months. Our patient is alive at the age of 30 months, and even though the disease process continues to be active,

it is not as severe as during the first weeks of life. She exhibits both physical and developmental retardation, but these may be due, in part, to the restriction of activity that has been necessary during a large part of her life.

Since it was our impression initially that we were dealing with a rapidly fatal disease, the empirical use of various forms of therapy seemed to be indicated in the hope that they might alter the expected course. Immediately after birth the child was isolated in a room by herself and placed in an open crib lined with plastic sheeting. She was handled as little as possible and then only by those who wore gowns, masks and sterile gloves. Various antibiotics were given singly or in combination in an attempt to prevent and eradicate secondary infections. Since the improvement occurring at puberty in certain mild types of epidermolysis bullosa may take place as a result of increased amounts of adrenal, ovarian or testicular hormones being produced at that time, therapy with such preparations was felt to be justifiable in our patient. Accordingly, during the second and third months of life, she was given courses of conjugated oestrogens, hydrocortisone and testosterone. No control periods of observation were carried out and we were unable to evaluate definitively the relative effectiveness of these drugs. Although the hormones may have played a role in altering the course of her disease, it was our clinical impression that meticulous nursing care, scrupulous isolation technique and the antibiotics that were used were extremely important. In addition an inherent difference between the severity of the disease process in our patient and

those previously reported may have contributed materially to her survival.

Summary

A child with epidermolysis bullosa hereditaria 'letalis' who is still alive at 30 months of age is reported.

Various forms of therapy were tried. It was felt that the survival of the patient for two and a half years, in contrast to all others previously reported who had died before the age of 16 months, was due either to an inherent difference in the disease process and/or to the careful nursing care, scrupulous isolation technique and antibiotic and hormone therapy that was used.

REFERENCES

- Calnan, C. D. (1954-55). *Gt Ormond Str. J.*, No. 8, p. 113.
 Cockayne, E. A. (1933). *Inherited Abnormalities of the Skin and its Appendages*, p. 118. London.
 Elliot, G. T. (1900). *N.Y. med. J.*, 71, 585.
 Engman, M. F. and Mook, W. H. (1906). *J. cutan. Dis.*, 24, 55.
 Fox, T. (1879). *Lancet*, 1, 766.
 Frank, D. J. and Kern, W. H. (1954). *Ohio St. med. J.*, 50, 679.
 Hebra, von (1870). Cited by Matheson, A. and Rosner, D. C.
 Henderson, A. T. (1955). *J. Pediat.*, 46, 186.
 Herlitz, G. (1935). *Acta paediat. (Uppsala)*, 17, 315.
 Kagen, M. S., Williams, L., Giffin, W. and Wiley, R. (1952). *Wis. med. J.*, 51, 766.
 Köbner, H. (1886). *Dtsch. med. Wschr.*, 12, 21.
 Lamb, J. H. and Halpert, B. (1947). *Arch. Derm. Syph. (Chicago)*, 55, 369.
 Langhof, H. (1952). *Derm. Wschr.*, 126, 764.
 Leland, L. S. and Hirschl, D. (1954). *A.M.A. J. Dis. Child.*, 87, 321.
 Lewis, I. C., Steven, E. M. and Farquhar, J. W. (1955). *Archives of Disease in Childhood*, 30, 277.
 Lucini, E. (1955). *Lattante*, 26, 38.
 Matheson, A. and Rosner, D. C. (1949). *Amer. J. Dis. Child.*, 78, 708.
 Schäffer, G. (1951). *Acta dermato-venereol. (Stockh.)*, 31, 704.
 Siemens, H. W. (1937). *Arch. Derm. Syph. (Berl.)*, 175, 590.
 Touraine, A. (1942). *Ann. Derm. Syph. (Paris)*, 8 ser., 2, 309.
 Winer, M. N. and Orman, J. M. (1945). *Arch. Derm. Syph. (Chicago)*, 52, 317.