

glucose. Results. Plasma levels of homocysteine were elevated in children with obesity, 42,18% of cases, compared to the control values (the mean  $8,98 \pm 1,73 \mu\text{mol/}$  vs  $6,1 \pm 2,4 \mu\text{mol/}$ ). Increased levels of homocysteine in obese children was correlated with body mass index and more important to the in obese children with hypertension (5 cases). Elevated Hcy were often associated with high total cholesterol  $\pm$  triglycerides in obese children compared with control values, normal values of blood glucose. Conclusions. Obesity in school children and especially association and the presence of high blood pressure werw associated with an increase in plasma homocysteine values often correlated with elevated total cholesterol  $\pm$  triglyceride levels. Research and systematic monitoring of values of plasma homocysteine correlated with cholesterol and triglyceride levels allows an objective estimation of cardiovascular risk in children with obesity and an indication for cardiovascular prevention effective measures.

### PO-0019 NON-INVASIVE HAEMODYNAMIC ASSESSMENT OF ANAESTHETIC INDUCTION IN ADOLESCENTS – A PILOT STUDY

<sup>1</sup>B Saikia, <sup>2</sup>H Wellesley, <sup>1</sup>J Brierley. <sup>1</sup>PICU, Great Ormond St Children's Hospital, London, UK; <sup>2</sup>Anaesthetic Department, Great Ormond St Children's Hospital, London, UK

10.1136/archdischild-2014-307384.699

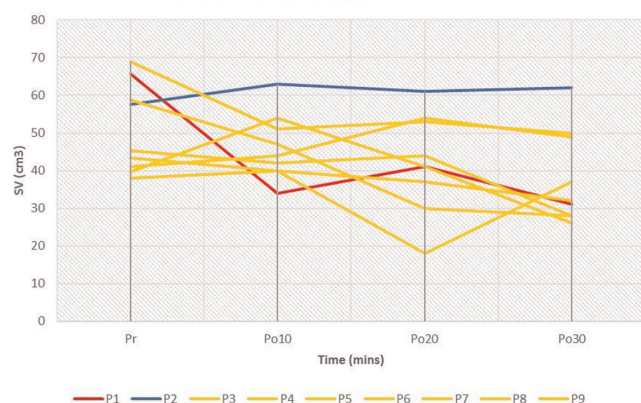
**Background** Little is known about the haemodynamic effects of commonly used paediatric anaesthetic drugs in teenagers. Previous 'gold-standard' invasive haemodynamic monitoring is inappropriate in well children, whereas children undergoing haemodynamic monitoring on ICU are not drug-naive.

**Aim** 6-month study to explore initial haemodynamic effects of commonly used induction agents during elective anaesthesia for orthopaedic conditions in healthy stable children.

**Method** Consent from those with parental responsibility obtained. All haemodynamic assessment performed using a non-invasive Doppler ultrasound (USCOM). Data collected: stroke volume (SV), stroke volume index (SVI), cardiac output (CO), cardiac index (CI), stroke volume variability (SVV), heart rate (HR) and blood pressure (BP). Times: Immediately prior to induction, then at 10, 20 and 30 min post induction.

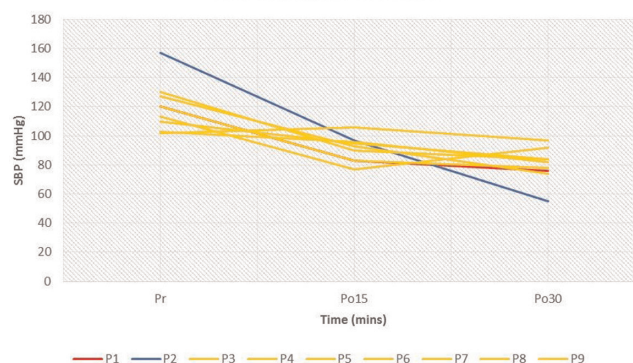
**Results** 9 patients studied – five female; age 11–15 years. Induction agents: Propofol 7; sevoflurane 1; nitrous 1. Descriptive hemodynamics: Propofol – slow and steady fall observed in SV, SVI, CO, CI, SBR, DBP and HR over time. Sevoflurane – same

Stroke Volume Changes Over Time



Abstract PO-0019 Figure 1

SBP Changes Over Time



Abstract PO-0019 Figure 2

but BP drop more rapid. Nitrous – steady SV, SVI, CO and CI with slow fall in HR but more pronounced fall in BP. No definite pattern could be predicted for SVV.

**Conclusion** Whilst this data is clearly limited in terms of patient number and variety of agents, it is the first description of the haemodynamic effects of induction of anaesthesia in well children. Whilst there were no deleterious effects, an understanding of the haemodynamic effects of these commonly used agents might lead to safer anaesthesia in more complex and critically ill children.

## Cardiology and Cardiac Surgery

### PO-0020 CHRONIC ESCHERICHIA COLI STERNAL WOUND INFECTION AND MEDIASTITIS AFTER HEART SURGERY FOR TETRALOGY OF FALLOT

O Kayabey, M Deveci, K Babaoglu, AE Arisoy, ES Arisoy. Department of Pediatrics, Kocaeli University Faculty of Medicine, Kocaeli, Turkey

10.1136/archdischild-2014-307384.700

**Background and aims** Surgical site infections after median sternotomy and repair of congenital heart diseases are rare but have a high morbidity and mortality in paediatric patients. These patients may require repeated surgical procedures including sternal debridement. We present a case who had chronic *Escherichia coli* surgical site infection and mediastinitis after complete repair of tetralogy of Fallot.

**Methods** A 2.7-year-old boy who underwent an uneventful surgical total correction procedure for tetralogy of Fallot 9 months before, was referred to our centre because of fever and swelling on sternal incision. Infective endocarditis was ruled out by echocardiographic examination. After ampicillin/sulbactam and clindamycin treatment, the abscess spontaneously drained. Cultures were positive for ESBL-producing *E. coli*. He had sternal debridement, appropriate antibiotic therapy and was discharged from hospital.

**Results** Six months later, he was admitted because of effluent from sternal incision scar. MRI of mediastinum revealed a deep sternal wound infection. ESBL-positive *E. coli* was isolated in cultures taken from the suppurative effluent. Mediastinitis was confirmed by exploratory sternotomy. Cultures of blood and mediastinal swabs were positive for the same organism. The child had an uneventful recovery after the surgical and medical treatment.