

received a blood transfusion in the 48 hrs preceding diagnosis. No cases of TRAGI were identified.

**Conclusion** In our population 83% of infants diagnosed with NEC had PCV < 42. Anaemia was associated with increased risk for developing NEC, we did not identify any increased risk relating to blood transfusion. Considering the possible causes for anaemia and refining transfusion thresholds in selected cases may be indicated. Further prospective studies may be helpful to identify potential critical Hct levels.

**287 CRP VALUES CAN DIFFERENTIATE BETWEEN A NORMAL POST-OPERATIVE RESPONSE AND SURGICAL COMPLICATIONS**

doi:10.1136/archdischild-2012-302724.0287

SP Sharif, SR Phelps. *Paediatric Surgery, The Royal London Hospital, London, UK*

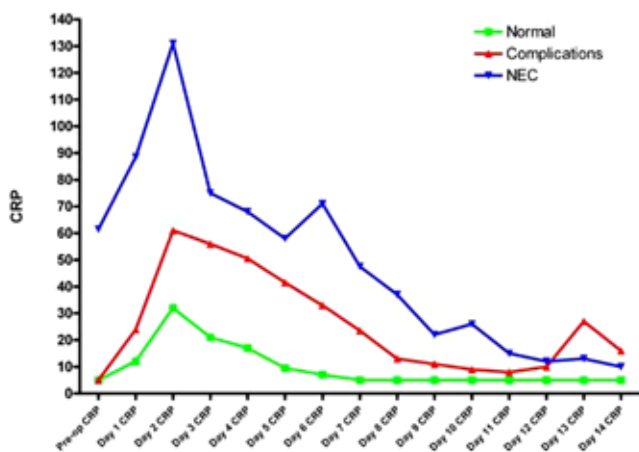
**Aims** A raised post-operative CRP is a source of great anxiety for surgeons and neonatologists. This study aims to assess the post-operative CRP response in neonates who undergo surgery in order to describe a normal physiological response to surgical trauma. This is compared to post-operative changes in neonates undergoing surgery specifically for NEC and neonates who develop surgical complications.

**Methods** A retrospective study was performed over a one year period (2010) analyzing consecutive neonates undergoing surgery. Daily WCC, platelet count and C-reactive protein measurements were analyzed on consecutive post-operative days in three distinct subgroups: control, surgical complications group and NEC.

**Results** There was a total of 81 patients (see Table 1).

Abstract 287 Table 1

	No. of Patients	Median gestational age	Median time to surgery (days)	Median birth weight (grams)
Control	53	37	4	2270
Complications	11	35	2	2500
NEC	17	25+2	23	785



Abstract 287 Graph 1

As shown in Graph 1 the post-operative CRP values for the control group and complications group were significantly different throughout the 12 day time period (p=0.01, Mann-Whitney U test). The CRP values for the control group were also significantly lower than the NEC group (p=0.0001, Mann-Whitney U test).

**Conclusion** The post-operative CRP trend was more important than a single result. This study quantified a physiological CRP

change in response to surgery in neonates. In particular, there was a significantly different CRP response in neonates who developed a post-operative complication.

**288 CLASSIFICATION OF BRAIN INJURY ASSOCIATED WITH NEONATAL ECMO. NATIONAL REVIEW OF 2 DECADES IN THE NETHERLANDS**

doi:10.1136/archdischild-2012-302724.0288

<sup>1</sup>M Raets, <sup>1</sup>J Dudink, <sup>2</sup>H Ijsselstijn, <sup>3</sup>A van Heijst, <sup>4</sup>M Lequin, <sup>2</sup>RJ Houmes, <sup>1</sup>I Reiss, <sup>1,5</sup>P Govaert, <sup>2</sup>D Tibboel. <sup>1</sup>Neonatology; <sup>2</sup>Intensive Care, Department of Pediatrics and Pediatric Surgery, Sophia Children's Hospital Erasmus Medical Center, Rotterdam; <sup>3</sup>Neonatology, Radboud University Nijmegen Medical Center, Nijmegen; <sup>4</sup>Pediatric Radiology, Sophia Children's Hospital Erasmus Medical Center, Rotterdam, The Netherlands; <sup>5</sup>Pediatrics, Koningin Paola Children's Hospital, Antwerp, Belgium

**Background and Aims** Brain injury is an important complication of neonatal Extra Corporeal Membrane Oxygenation (ECMO). Unilateral carotid artery and jugular vein cannulation (often with ligation), in combination with systemic heparinisation, increases the risk of brain injury in an already vulnerable group of patient. The reported prevalence of brain injury ranges from 10–52% of patients treated with neonatal ECMO. Monitoring of intracranial lesions during the ECMO procedure is therefore important for treatment and prediction of outcome.

Our objective is to study incidence and classification of ultrasound proven brain injury during neonatal ECMO in the Netherlands.

**Methods** Retrospective, nationwide study (Rotterdam and Nijmegen), spanning two decades. Cranial ultrasound images were reviewed by two independent investigators, without knowledge of primary diagnosis, outcome or type of ECMO.

**Results** 676 neonates with neonatal ECMO were studied. ECMO type was V-A in 88%. Brain abnormalities were detected in 17.3% of patients: primary hemorrhage was diagnosed most frequent (8.8%). A noticeable result was found in stroke patients (5% of the total group), where there was a significant predominance of lesions in the left hemisphere. Lobar haematoma (prevalence 2.2%) was also significantly left sided predominant.

**Conclusion** Our study shows an incidence of ECMO-associated neonatal brain injury in the Netherlands in 17.3%. Left hemisphere lesion preference suggests that shift of brain perfusion from right to left is more important than large vessel ligation in the neck. Prevention has to focus on embolism and on management of this perfusion shift.

**289 THE EFFECT OF PERINATAL INFECTION ON NEURODEVELOPMENTAL OUTCOME IN NEWBORNS WITH HYPOXIC-ISCHEMIC ENCEPHALOPATHY**

doi:10.1136/archdischild-2012-302724.0289

<sup>1</sup>M Jenster, <sup>2</sup>T Ruel, <sup>2</sup>SL Bonifacio, <sup>2</sup>EE Rogers, <sup>3</sup>EW Tam, <sup>4</sup>AJ Barkovich, <sup>3</sup>DM Ferriero, <sup>3</sup>HC Glass. <sup>1</sup>University of Groningen, Groningen, The Netherlands; <sup>2</sup>Pediatrics; <sup>3</sup>Neurology & Pediatrics; <sup>4</sup>Radiology & Biomedical Imaging, University of California, San Francisco, CA, USA

Studies of preterm neonates suggest that infection may potentiate hypoxic-ischemic (HI) brain injury. In term neonates, infection is a risk factor for encephalopathy and cerebral palsy. Whether it potentiates the risk of brain injury and adverse outcome in the setting of hypoxic-ischemic encephalopathy (HIE) is not clear.

The charts of 257 term newborns with HIE were reviewed for signs of maternal and infant infection, including chorioamnionitis and proven or suspected sepsis. Multivariate logistic regression was used to assess the effect of infection on severity of brain injury as seen on a neonatal MRI (normal-mild vs. moderate-severe), and on risk of adverse neurodevelopment at 30 months in a subset of