

**Conclusion** In selected families, IHBW reduces hospital stay in managing NAS, without increasing morphine dose. Concerns regarding infant welfare limit the number of infants suitable for this management pathway.

**1054 NEONATAL ABSTINENCE SYNDROME: HAS THE ONSET OF SYMPTOMS CHANGED IN THE LAST DECADE?**

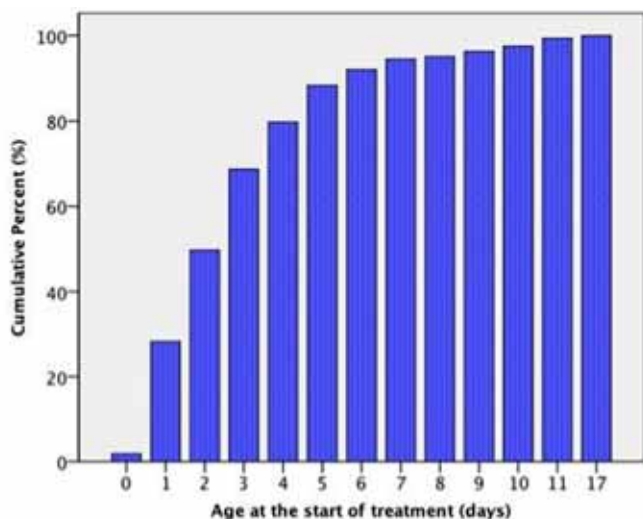
doi:10.1136/archdischild-2012-302724.1054

<sup>1</sup>C Smirk, <sup>1</sup>E Bowman, <sup>1,2</sup>LW Doyle, <sup>1</sup>COF Kamlin. <sup>1</sup>Royal Women's Hospital, Parkville; <sup>2</sup>Department of Obstetrics, University of Melbourne, Melbourne, VIC, Australia

**Background and Aims** Neonatal abstinence syndrome (NAS) often presents in the first 72 hours of life. Observation of at-risk infants is important to ensure prompt treatment if necessary. In 1998 at this hospital, 90% of infants requiring treatment for NAS commenced in the first week after birth. We aimed to describe the commencement of treatment for infants with NAS in the last decade.

**Methods** We undertook a retrospective review of babies treated pharmacologically for NAS during 2001–2010 at The Royal Women's Hospital, Melbourne. Our guidelines recommend 7 days post-natal observation for infants at risk of NAS. Infants were admitted to the neonatal unit if they were felt to require treatment or had other neonatal complications.

**Results** 163 infants were treated for NAS; 85% and 8% of the mothers were hepatitis C and B positive respectively. In-utero substance exposure included opioids (97%), cannabis (29%) and benzodiazepines (25%). Over 90% of infants were treated by day 7 of life, most of whom had been admitted by day 5 (Figure). There were no differences in the age of treatment if the infant was exposed to opioids alone or multiple classes of drugs in utero.



Abstract 1054 Figure 1 Infants treated for NAS by day of life

**Conclusion** In the last decade, the timing of first medication for NAS is unchanged. Infants of chemically dependent mothers require a minimum of 7 days of in-patient observation.

**1055 NEUROIMAGING PROGNOSTIC CATEGORIZATION IN NEWBORNS WITH SYMPTOMATIC CONGENITAL CYTOMEGALOVIRUS INFECTION (SCCI)**

doi:10.1136/archdischild-2012-302724.1055

<sup>1</sup>A Alarcón, <sup>2</sup>M Martínez-Biarge, <sup>2</sup>F Cabañas, <sup>2</sup>J Quero, <sup>1</sup>A García-Alix. <sup>1</sup>Neonatology, Hospital Sant Joan de Déu, Universitat de Barcelona, Esplugues de Llobregat; <sup>2</sup>Neonatology, Hospital Universitario La Paz, Madrid, Spain

**Background and Aims** In SCCI, Noyola's neuroimaging prognostic categorization is restricted to destructive abnormalities.

**Objective** To ascertain the predictive ability of a classification including destructive, developmental abnormalities and white matter signal changes on MRI.

**Methods** Population: Patients with SCCI born between 1993–2009. Setting: La Paz Tertiary University Hospital.

**Design** Prospective observational. Neuroimaging (US, CT and/or MRI) findings were graded by Noyola's and our scoring system (Table).

Abstract 1055 Table 1 Classification of neuroimaging

Score	Noyola's scoring system	New scoring system
0	No abnormalities	No abnormalities
1	Single punctate calcification and/or lenticulostriate vasculopathy	Same as Noyola and/or focal white matter signal abnormality on MRI
2	Multiple discrete calcifications and/or moderate-severe ventriculomegaly	Same as Noyola and/or diffuse white matter signal abnormality on MRI
3	Extensive calcifications and/or brain atrophy	Same as Noyola, neuronal migration disorder, corpus callosum dysgenesis and/or cerebellar hypoplasia

Blinded follow-up assessment included: neurologic examination, cerebral palsy scoring (GMFCS), cognitive evaluation (BSID-III, WPPSI-III or WISC-IV), behavioral assessment (CBCL) and evaluation of seizures, hearing or visual loss.

**Results** Twenty-six patients were included, 3 of which died. Mean age at follow-up was 8.7±5.3y (19m–18.0y), and 15(65%) surviving patients had moderate-severe disabilities. Our neuroimaging classification showed higher predictive ability than Noyola's (AUC 0.94±0.04 vs 0.89±0.06, Table).

Abstract 1055 Table 2 Predictive values for adverse outcome, scores 2–3

Scoring system	Sensitivity	Specificity	PPV	NPV
Noyola's	61%	100%	100%	53%
Present	83%	100%	100%	72%

**Conclusions** In SCCI, a comprehensive neuroimaging analysis including destructive and developmental abnormalities is highly predictive of neurodevelopmental outcome.

**1056 MEGA CISTERNA MAGNA DIAGNOSTIC DILEMMA**

doi:10.1136/archdischild-2012-302724.1056

<sup>1</sup>M Yar, <sup>2</sup>R Syed, <sup>1</sup>MM Abou Al-Seoud. <sup>1</sup>Neonatal Division, Paediatric Department; <sup>2</sup>Paediatric Neurology Division, Paediatric Department, King Fahad Armed Forces Hospital, Jeddah, Saudi Arabia

**Background and Aim** The prenatal diagnosis of posterior fossa dysgenesis remains challenging.

**Mega-cisterna magna (MCM)** is applied to prominence of the retro-cerebellar CSF space and may not be associated with abnormalities. The clinical significance of this finding varies. Diagnostic modalities of the MCM are by ultrasound and or MRI.

Our aim is to:

- Determine the Incidence of isolated dilated MCM in our population.
- Compare the accuracy of fetal ultrasound with postnatal neuroimaging.
- Report the associated central nervous system anomalies.

**Method** We identified retrospectively all reported cases of isolated dilated cisterna magna from 1/January 2007 till 31/7/2011.